

Advancing the Care of Cancer Patients with Vertebral Compression Fractures—A Radiation Oncology Expert Panel Discussion

Moderator: Jon Strasser, MD

Radiation Oncologist, Thomas Jefferson University and Helen F Graham Cancer Center

Expert Panel Members: Neha Amin, MD,¹ Gregg Dickerson, MD,² Nancy Cersonsky, MD,³ Michelle Stinauer, MD,¹ Brian Petersen, MD⁴ and Timothy Birney, MD⁵

1. Radiation Oncologist, University of Colorado Denver; 2. Radiation Oncologist, Denver CyberKnife; 3. Radiation Oncologist, Valley Radiotherapy Associates Medical Group, Swedish Medical Center, Englewood; 4. Interventional Radiologist, University of Colorado Hospital; 5. Orthopedic Surgeon, Western Orthopaedics, Denver

Introduction

A closed roundtable discussion on 'Advancing the Care of Cancer Patients with Vertebral Compression Fractures' was held in Denver, Colorado, on November 16, 2010. The attendees included six invited local experts—four radiation oncologists, an interventional radiologist, and an orthopedic surgeon. The moderator, Jon Strasser, MD, a radiation oncologist, opened the meeting by explaining that its goal was to identify the barriers to managing vertebral compression fractures (VCFs) in cancer patients and discuss available treatment options. The focus would be on three topics: current treatment practice for spinal metastases; treatment goals in the presence of VCFs; and minimally invasive procedures for VCFs. Each topic is allocated a separate section of the following report of the discussion.

Keywords

Radiation oncology vertebral compression fracture, cancer patients, spinal metastases, cancer treatment options

Disclosure: Jon Strasser, MD, is a consultant for Medtronic. The Kyphon Products Division of Medtronic hosted and supported the expert panel discussion.

Received: October 5, 2011 **Accepted:** January 9, 2012 **Citation:** *Oncology & Hematology Review*, 2012;8(1):12–7

Correspondence: Jon Strasser, MD, Thomas Jefferson University and Helen F Graham Cancer Center, Radiation Oncology, 4701 Oglethorpe-Stanton Rd., S-1110, Newark, DE 19713. E: jstrasser@christianacare.org

Support: The publication of this article was funded by Medtronic. The views and opinions expressed are those of the panel members and not necessarily those of Medtronic.

Section 1. Current Treatment Practice for Spinal Metastases

Dr Strasser, a radiation oncologist, initiated the presentation with an overview of the manifestation of spinal metastases, stating that these develop in about half of all cancer patients. The median survival after bone metastases is 12 months with prostate cancer and five months with lung cancer, but it is two to three years in patients with breast cancer and multiple myeloma.¹⁻⁴ Therefore, it is important to address bone metastases in these patients. Treatment is especially important if patients develop fractures and experience pain.

Bone metastases lead to skeletal-related events, including fractures, pain, spinal cord compression, and hypercalcemia. Spinal metastases can be classified as osteolytic or osteoblastic; radiosensitive or radioresistant; or by spinal cord location. Osteoblastic vertebral lesions, which are common in patients with prostate cancer, are characterized by increased bone density and decreased bone stiffness. Osteolytic bone lesions, which are common in patients with

multiple myeloma, are characterized by decreased bone density, bone stiffness, and bone strength. Patients with osteolytic lesions have a higher risk of fractures.

When managing patients with spinal metastases, it is important to consider neurological aspects (e.g., degree of epidural cord compression, myelopathy, or radiculopathy), oncological aspects (e.g., tumor histology, radiosensitivity, and prognosis), mechanical instability, systemic disease, and patient preference for treatment.

Treatment goals are generally achieved by using a combination of complementary systemic and local therapies. Systemic therapy is used to improve patient survival, slow the progression of the disease, and prevent future events. Systemic therapy options for spinal metastases include steroids, bisphosphonates, chemotherapy, hormonal agents, and radiopharmaceuticals. Local therapies include surgery (e.g., spine stabilization) and radiation. Local therapy is used to control pain, restore anatomy, ablate a systemic tumor, and stabilize a fracture.

Reasons for performing open surgery for spinal metastases include tissue confirmation, pain relief, spine stabilization, anterior decompression, and neurologic decompression. Open surgery is a major procedure—patients need a prolonged rehabilitation (four to six weeks of recovery)—and it may not be suitable for some of them. Surgery can decompress nerves and restore anatomy, but it generally cannot treat the tumor.

Reasons for using conventional radiation to treat patients with bone metastases are that radiation treats the tumor, provides local pain control, delays or prevents local progression, and is relatively non-invasive. Problems with radiation therapy are that compression fractures are still possible after radiation; the bone is weakened; radiation is myelosuppressive; and it does not stabilize the fracture.

Dr Strasser described newer forms of radiation therapy: radiosurgery and intensity-modulated radiotherapy. The advantages are that it provides more precision, minimizes tissue toxicity, gives the ability to re-radiate, and is a non-invasive alternative to surgery. The disadvantages are that the patient's vertebral compression fracture (VCF) is not stabilized; the patient may be in pain and unable to tolerate immobilization; and the procedure is labor-intensive, lengthy, and costly. For mechanical stabilization of VCFs, radiation alone is not enough, so minimally invasive surgical techniques may be appropriate.

In a treatment algorithm for spinal metastases put forth by Gasbarrini et al. in Italy,⁵ patients with greater impairment are treated by surgical excision, and patients with more stable fractures are treated using less invasive techniques, such as local radiation and balloon kyphoplasty (see Box 1 for safety information regarding this procedure). Similar to open surgery, balloon kyphoplasty does not treat the tumor itself.

Discussion of the Treatment Algorithm Proposed by Gasbarrini et al.

Q: About how many cancer patients with spinal metastases do you see on average per week?

Responses from the faculty ranged from none (Dr Birney, who sees a lot of patients with multiple myeloma or lymphoma) to one to three per week (Dr Cersonsky), more than five a week (Dr Stinauer and Dr Amin), and at least seven a week (Dr Petersen). Dr Dickerson, a radiation oncologist with Denver CyberKnife, a free-standing (i.e., non-hospital-based) facility, said that most of his spinal radiosurgery is for tumors and meningiomas. Dr Petersen, an interventional radiologist at the University of Colorado Hospital, said patients who are referred to him predominantly have multiple myeloma. Dr Amin, from the University of Colorado Denver, gets referrals from Denver Health Veterans Affairs and sees patients with 'lung, breast, and prostate (cancer) ... the whole gamut.'

Q: In light of the discussed considerations and options, do you follow a specific treatment algorithm when making decisions for your cancer patients with spinal metastases?

Dr Stinauer said that treatment is not standardized, but rather depends on the provider that the patient sees and the amount of metastases the patient has. She added that she thought the providers could do better in terms of referring patients for kyphoplasty. Dr Dickerson said he followed a protocol. 'If there is any instability or existing vertebral compression fracture, I will refer to orthopedic or interventional or

Box 1: Important Safety Information

The complication rate with Kyphon® Balloon Kyphoplasty (Medtronic) has been demonstrated to be low. There are risks associated with the procedure (e.g., cement extravasation), including serious complications and, although rare, some of them may be fatal. For complete information regarding indications for use, contraindications, warnings, precautions, adverse events, and methods of use, please refer to the 'Instructions for Use' included with the product.

neurosurgery just to do the balloon kyphoplasty or vertebroplasty procedure, and then [usually follow up] with 5-fraction course radiosurgery.' Dr Cersonsky, a radiation oncologist, said she generally refers patients with VCFs for vertebroplasty or balloon kyphoplasty and then follows that treatment with radiation therapy if warranted. These referrals include patients who, in her opinion, have pain that would not be eased by radiation and patients who have at least a three-month life expectancy. If, as is sometimes the case, the first neurosurgeon does not agree to do the procedure, she refers the patient to a second neurosurgeon. Dr Strasser asked, 'Does your practice parallel the Chow et al. data' that show good response but still pain in patients who are not treated with up-front stabilization?' Dr Stinauer agreed with this assessment, adding that the majority of patients in her practice get some pain relief.

'If there is any instability or existing vertebral compression fracture, I will refer to orthopedic or interventional or neurosurgery just to do the balloon kyphoplasty or vertebroplasty procedure, and then [usually follow up] with 5-fraction course radiosurgery.'—Dr Dickerson

Q: What is your flow in terms of managing patients with spinal metastases?

Dr Stinauer and Dr Amin, who are radiation oncologists, said that patients were mostly coming to them from medical oncology. 'So it is up to us to then get neurosurgery involved,' said Dr Stinauer. She added that patients often wanted to try minimally invasive treatment (i.e., radiation) first and, if that treatment did not help them within four weeks, they would then consult a neurosurgeon. Dr Amin added that, although it is often them who refer patients to neurosurgery, a few patients who had been referred to her had already undergone balloon kyphoplasty. Dr Strasser asked Dr Birney, the orthopedic surgeon in the group, where his referrals were coming from. Dr Birney said that medical oncologists are largely the people who are sending him multiple myeloma patients seen at the Rocky Mountain Cancer Center. 'We have done a good job of educating them,' he added. 'They are paying attention to their spine MRIs [magnetic resonance imaging scans], trying to get them treated, particularly in preparation for transplant or, if they forgot to do it, post-transplant.' Dr Petersen said that it is largely medical oncologists who are sending him patients from the myeloma center.

Q: At what steps are you making decisions versus other members of the multidisciplinary care team? When it is not you making the decision, who is? At what steps are you AND other members of the multidisciplinary care team making decisions together?

Dr Stinauer said that they have tumor boards for each body site, but they do not really discuss bone metastases in a multidisciplinary care team.

Dr Amin, who works at the same center, added that there is usually a one-on-one discussion with the patient's medical oncologist. Dr Stinauer said that medical oncology does not usually refer patients simultaneously to them (radiation oncology) and to a surgeon; patients come to radiation oncology first. She agreed with Dr Strasser that the radiation oncologist is usually the person who brings up the issue of stabilization.

'The radiation oncologist is usually the person who brings up the issue of [fracture] stabilization.'—Dr Stinauer

Q: What criteria dictate the flow or order of these decisions? Are you referring patients for surgery before radiation? Or vice versa? Why? What is the rationale for the order of these decisions? What are the advantages and disadvantages?

Dr Cersonsky said that it is mostly pain that drives her decision to refer patients for stabilization. 'I treat a lot of breast cancer patients, and when they present with bone-only disease, they generally have very good survival times, and I think that they are very good patients to refer for procedure,' she said. Dr Dickerson said that in patients with renal carcinoma, for example, even high thoracic lesions can be at risk of collapse shortly after radiosurgery is done. 'If we do not do up-front stabilization on a big bulky lesion involving T3 or T4, we used to do a policy of monitoring them with MRI about two weeks after radiosurgery,' he said. Most patients want a minimally invasive procedure until they hear what can happen if they do not try stabilization first. Dr Petersen said they are waiting for patients' vertebrae to fracture before they treat them. Dr Dickerson feels early intervention should be decided on a case-by-case basis, since there are limited data available to definitively demonstrate a clinical benefit for this approach across all patient profiles.

Q: Does treatment with radiosurgery change your goals for stabilizing the spine? Is spinal stabilization important in your decisions?

Dr Amin said that they wait to see how the patient is doing and then decides if they will stabilize the patient's spine. More often than not, if the patient is not experiencing pain, even if they have a fracture, they will not stabilize them, added Dr Stinauer. Dr Dickerson said that it depends on the size of the lesion. 'If it is a small lesion, then a 16 to 18 Gy times one, nothing else,' he said. 'If they have pain, I tend to send them for evaluation to one of the surgeons.'

Section 2. Treatment Goals in the Presence of Vertebral Compression Fractures

In the US, the incidence of cancer-induced VCFs is estimated to be between 75,000 and 100,000 cases a year, mostly in patients who have stage III and IV prostate cancers (32 %), all stages of multiple myeloma (22 %), stage IV lung cancer (20 %), stage IV breast cancer (6 %), and other cancers (20 %). Fractures clearly have a negative impact on survival. The relative risk of death is significantly higher in patients with breast cancer, multiple myeloma, or prostate cancer who also have fractures.⁷⁻¹⁴

Kyphosis due to VCFs has been associated with compression of abdominal contents, early satiety, weight loss, decreased lung function, increased risk of death from lung disease (e.g., pneumonia), and increased risk of further fractures due to spinal instability.

Kyphosis has also been associated with chronic pain, increased dependence on family members, decreased ability to perform activities of daily living, and partial to complete immobility. Spinal cord compression and neurological consequences have been documented in some cases of untreated VCFs; patients with VCF may also have psychological consequences.

The goals of oncology care are to improve survival, maintain patients' quality of life and function, and prevent or manage further complications.

In patients with VCFs, pain can originate in the tumor itself (e.g., due to the release of inflammatory mediators or stretching of the periosteum), in which case the pain manifests at night or in the early morning, responds to steroids, and improves with activity. Or pain can come from the structural instability of the spine, in which case it is incident- and movement-related and is exacerbated by sitting or standing.

Physicians try to aggressively stabilize fractures of the ankle, wrist, and hip. However, for one of the most important structures of the body—the spine—the standard of care is to leave it in a compromised condition.

Discussion of Treatment Goals

Q: Approximately how many of your cancer patients with spinal metastases present with VCFs?

Dr Cersonsky estimates that 10–15 % of her lytic patients with spinal metastases present with VCFs. Patients seen by the interventional radiologist Dr Petersen, however, all present with fractures, and many of the myeloma patients present with back pain and spinal fracture.

Q: Does the algorithm we discussed earlier for making decisions for your cancer patients with spinal metastases differ when VCFs are present? If so, are there steps added to the earlier algorithm?

Dr Amin and Dr Stinauer said that they do not change their treatment but they think they should. 'I think we still radiate patients who present with VCFs and then we can refer them, but I think that there needs to be change,' said Dr Amin. Dr Cersonsky said she tends to refer those patients first for vertebroplasty or balloon kyphoplasty, again leaving that up to the neurosurgeon, before she treats them with radiation therapy, as long as there is no spinal cord compression. Dr Stinauer said that previously, patients were not living as long but now, with longer survival, we should treat VCFs aggressively. Dr Amin added that in the past they were not thinking about stabilization of the spine, but instead were thinking about a patient's fever and back pain.

'I tend to refer patients with spinal metastases and vertebral compression fractures for stabilization first, leaving the decision up to the neurosurgeon on whether to perform balloon kyphoplasty or vertebroplasty, before I treat them with radiation therapy, as long as there is no cord compression.'—Dr Cersonsky

Dr Amin also said that, when she sees VCFs and tumor, she thinks that radiation will help cure the tumor cells but may not alleviate the pain. A lot of patients may need both treatments, she added. She is uncertain about whether it is better to irradiate and then send the patient for balloon kyphoplasty or vice versa, because what if the tumor is still there? Dr Strasser said that he and Dr Dickerson tend to stabilize up-front.

Q: Who leads patient management decisions for your patients who have been referred?

Dr Cersonsky and Dr Stinauer both agreed that the radiation oncologist decides how referred patients will be managed.

Q: What criteria dictate the flow or order of these decisions? What is the rationale for the order of these decisions? What are the advantages and disadvantages?

The group agreed with Dr Strasser that they are first stabilizing patients for pain control and then giving them radiation. Dr Cersonsky said that they are seeing a significant, immediate change in pain after balloon kyphoplasty or vertebroplasty, which is very nice. Dr Stinauer added that they are seeing those patients who do not have a good response to balloon kyphoplasty and need to be evaluated for further treatment, such as radiation therapy: the ones with a good response are not coming to see them right away.

Q: Do your goals differ when managing cancer patients with spinal metastases once VCFs are present?

Dr Cersonsky said that with a compression fracture, stabilization is required, because you can have bone fragments protruding into the canal, which can be devastating. ‘Then the patient absolutely needs a neurosurgical referral, because no amount of radiation is going to alleviate their pain or change that problem,’ she added. Generally, those patients are not good candidates for vertebroplasty or balloon kyphoplasty, said Dr Dickerson.

Dr Birney said that in patients with posterior disease who have no spinal cord compression or radiculopathy, doing a balloon kyphoplasty is a strategic move, because if the patients have further collapse, they will experience severe pain. ‘You are injecting cement from anterior to posterior, and the minute you start to see any potential posterior migration of cement, that is where you stop,’ he said. In his view, ‘if a surgeon is skilled and is cautious, having posterior cortical disruption is not a contraindication.’ He said that imaging is important in deciding how high to go—the highest lesion he has treated was a T2 lesion. In the lateral view, the shoulders get in the way of visualization, he added.

‘Radiation will help cure the tumor but may not alleviate pain caused by the compression fracture. A lot of patients may, therefore, need both spinal stabilization and radiation therapy.’—Dr Amin

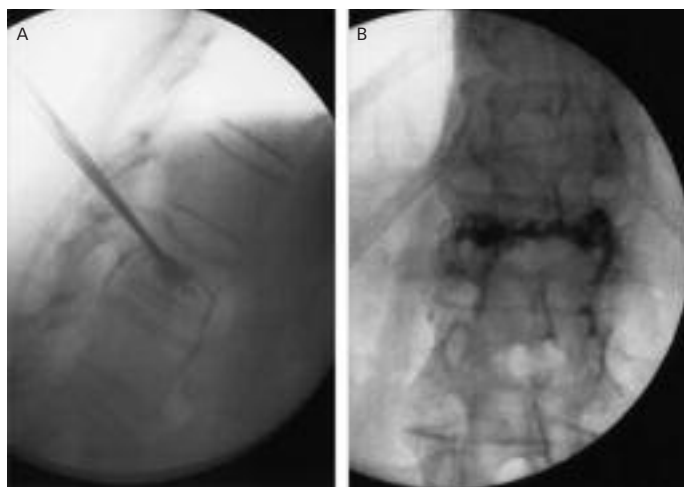
Q: What barriers are you facing when managing these patients (e.g., insurers, timing of procedures)?

Dr Petersen said that almost all his patients are outpatients, unless it is a 4 pm start time. Dr Birney agreed that oncology patients who undergo the procedure early in the day can generally go home the same day, except some myeloma patients who need to stay longer. Dr Cersonsky said she is not yet facing any problems with insurers or payers.

Q: What are you doing for stabilization before and after radiation? How do you decide the timing of the treatment?

Dr Strasser summarized that it sounds like Dr Amin and Dr Stinauer typically radiate first and then go back to deal with fractures, if

Figure 1: Vertebroplasty Procedure



A: Lateral image obtained during the procedure demonstrating needle trajectory with polymethylmethacrylate (PMMA) bone cement fill. B: Anteroposterior image showing final PMMA bone cement casting.

necessary, whereas Dr Dickerson and Dr Cersonsky think about doing the stabilization upfront.

Q: How do you decide between the non-surgical management and the interventional approach?

Dr Birney said that 50 years ago, when people had hip fractures, physicians would put them on bed rest and Buck’s traction for six weeks—unlike now, when they are aggressively treated, added Dr Strasser. Dr Birney asked, ‘Why would you treat a vertebral compression fracture and brace it for six weeks, if you can offer the patient [an intervention that results in] quicker pain relief and the potential for vertebral body height [kyphosis] correction?’

‘Why would you treat a vertebral compression fracture and brace it for six weeks, if you can offer the patient [an intervention that results in] quicker pain relief and the potential for vertebral body height [kyphosis] correction?’—Dr Birney

Q: How do you decide whether you are going to use balloon kyphoplasty or vertebroplasty?

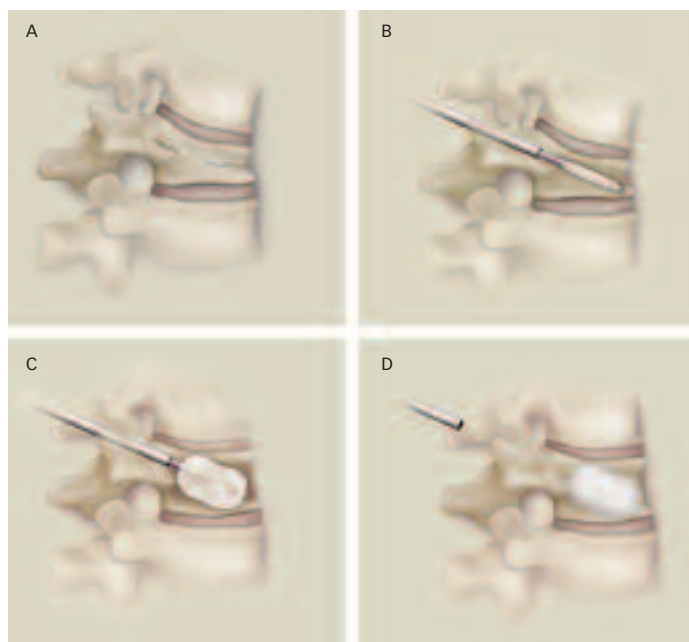
Dr Cersonsky said the choice is typically made by the neurosurgeon or the interventional radiologist.

Section 3. Minimally Invasive Procedures for Vertebral Compression Fractures

Interventional radiologist Dr Petersen said he uses both balloon kyphoplasty and vertebroplasty, depending on the circumstances. He went on to explain that the complication rates from cement extravasation in balloon kyphoplasty versus vertebroplasty depend on how you define these rates. Orthopedic surgeon Dr Birney said he has the same philosophy as Dr Petersen: he is not concerned if he gets minor extravasation in an unimportant, benign location.

Vertebroplasty is the injection of bone cement into the fractured vertebral body to reduce pain and stabilize the fracture (see *Figure 1*).

Figure 2: Balloon Kyphoplasty Procedure



A: Step 1—A hollow instrument is used to create a small pathway into the fractured bone; a small, orthopedic balloon is guided through the instrument into the vertebra; the incision site is approximately 1 cm in length. B: Step 2—The balloon is carefully inflated in an attempt to raise the collapsed vertebra and restore vertebral body height (represents initial inflation). C: Step 3—The cavity created by the balloon is filled with polymethylmethacrylate (PMMA) bone cement. D: Step 4—The PMMA bone cement is designed to form an internal cast to hold the vertebra in place.

With balloon kyphoplasty, a balloon is inserted into the fractured vertebra and inflated to create a space (see *Figure 2*). Bone cement (polymethylmethacrylate [PMMA]) can then be instilled into that space. Typically, more viscous bone cement can be used.

In the US, vertebroplasty has been performed since 1995 and balloon kyphoplasty has been performed since 1998. Both are percutaneous procedures and both provide pain relief. However, unlike vertebroplasty, balloon kyphoplasty creates a void in the bone, and it was designed to potentially correct angular deformity and restore vertebral height.

Dr Strasser went on to describe three studies¹⁵ that compared balloon kyphoplasty and vertebroplasty, and one study¹⁶ that looked at combined balloon kyphoplasty and radiosurgery. The panel also reviewed preliminary data from the Cancer patient fracture evaluation (CAFE) study, a randomized controlled multicenter study of balloon kyphoplasty versus non-surgical management in cancer patients. These results have since been published in *The Lancet Oncology*.¹⁷

Kyphoplasty and Radiosurgery

Gerszten et al. examined 26 patients with spine metastases who underwent kyphoplasty to mechanically stabilize the fracture plus radiosurgery for tumor control.¹⁸ The patients had a 92 % improvement in back pain within one month, and more than half the patients had some correction of kyphotic deformity. The optimal

treatment sequence remains to be determined in a new, controlled study, said Dr Strasser, adding that, for now, the treatment sequence should be determined on a case-by-case basis.

Discussion of Minimally Invasive Procedures

The final part of the expert panel discussion led by Dr Strasser related to vertebroplasty and balloon kyphoplasty for VCFs in cancer patients.

Q: Describe your experience with minimally invasive treatments.

Dr Stinauer said that they tend to do radiation alone and see how that works first, and they will consider balloon kyphoplasty first for pain. Dr Amin said that they get patients with bone metastases all the time, and they do ‘an “automatic” 1 x 8 Gy’ radiation procedure.

Q: What criteria shape your decision to refer cancer patients for balloon kyphoplasty rather than an open procedure? Is it test results? Or timing?

Dr Stinauer said that her decisions are based on patient symptoms. Dr Amin added that they defer to the neurosurgeons. In turn, Dr Birney said that the type of surgery is shaped by the patient’s general health or the disease status in terms of the structural aspect of the spine.

Q: Is there a patient profile for those patients you would not refer for balloon kyphoplasty? MRI findings?

Dr Birney said that in ‘any patient who has cord compression, significant radicular pain, [or] epidural spread ... obviously there is going to have to be a neurologic open procedure.’ Dr Petersen said that treating asymptomatic fractures would probably not benefit patients, ‘but those that are lighting up on your MRI ... are the ones that you are really going to help with fracture stabilization.’

Q: What are the barriers to utilization (e.g., surgeons, financial reasons)?

The group agreed with Dr Strasser’s summary of their previous comments: there are not a lot of barriers in terms of insurance or payers.

Q: What are your opinions about integrating balloon kyphoplasty with radiation therapy?

Dr Birney said that balloon kyphoplasty should be done first, because ‘you can cause bone necrosis that makes the bone harder, and you are less likely to regain height and have good expansion of your bones.’ However, it would be hard to tell this to a radiation oncologist, he added.

Q: What is your experience with patients who have already been treated with radiation therapy?

Dr Dickerson said that in patients who have had radiation and then develop a compression fracture, he would like to see if there is any metabolic activity, or if it is just a benign compression fracture. Dr Petersen said the morphology on MRI is usually fairly indicative of what is going on. He agreed with Dr Strasser, who said that if you stabilize the compression fracture up-front, it is not going to re-fracture.

Dr Strasser ended the expert panel discussion by thanking everyone for providing insights into their respective clinical practices. ■

1. Selvaggi G, Scagliotti GV, Management of bone metastases in cancer: a review, *Crit Rev Oncol Hematol*, 2005;56:365–78.
2. Nielsen OS, Munro AJ, Tannock IF, Bone metastases: pathophysiology and management policy, *J Clin Oncol*, 1991;9:509–24.
3. Koenders PG, Beex LV, Kloppenborg PW, et al., Human breast cancer: survival from first metastasis. Breast Cancer Study Group, *Breast Cancer Res Treat*, 1992;21:173–80.
4. Body JJ, Effectiveness and cost of bisphosphonate therapy in tumor bone disease, *Cancer*, 2003;97(3 Suppl.):859–65.
5. Gasbarrini A, Cappuccio M, Mirabile L, et al., Spinal metastases: treatment evaluation algorithm, *Eur Rev Med Pharmacol Sci*, 2004;8:265–74.
6. Chow E, Harris K, Fan G, et al., Palliative radiotherapy trials for bone metastases: a systematic review, *J Clin Oncol*, 2007;10:1423–36.
7. Hortobagyi GN, Theriault RL, Porter L, et al., Efficacy of pamidronate in reducing skeletal complications in patients with breast cancer and lytic bone metastases, *New Engl J Med*, 1996;335:1785–91.
8. Berenson JR, Lichtenstein A, Porter L, et al., Efficacy of pamidronate in reducing skeletal events in patients with advanced multiple myeloma, *New Engl J Med*, 1996;334:488–93.
9. Brincker H, Westin J, Abildgaard N, et al., Failure of oral pamidronate to reduce skeletal morbidity in multiple myeloma: a double-blind placebo-controlled trial. Danish-Swedish co-operative study group, *Br J Haematol*, 1998;101:280–6.
10. McCloskey EV, MacLennan ICM, Drayson MT, et al., A randomized trial of the effect of clodronate on skeletal morbidity in multiple myeloma, *Br J Haematol*, 1998;100:317–25.
11. Melton LJ, Kyle RA, Achenbach SJ, et al., Fracture risk with multiple myeloma: a population-based study, *J Bone Miner Res*, 2005;20:487–93.
12. Mhaskar R, Redzepovic J, Wheatley K, et al., Bisphosphonates in multiple myeloma (review), *Cochrane Database Syst Rev*, 2002:CD003188:1–32.
13. Berruti A, Dogliotti L, Bitossi R, et al., Incidence of skeletal complication in patients with bone metastatic prostate cancer and hormone refractory disease: predictive role of bone resorption and formation and formation markers evaluated at baseline, *J Urol*, 2000;164:1248–53.
14. Diamond TH, Bucci J, Kersley JH, et al., Osteoporosis and spinal fractures in men with prostate cancer: risk factors and effects of androgen deprivation therapy, *J Urol*, 2004;172:529–32.
15. Han S, Wan S, Ning L, et al., Percutaneous vertebroplasty versus balloon kyphoplasty for treatment of osteoporotic vertebral compression fracture: a meta-analysis of randomised and non-randomised controlled trials, *Int Orthop*, 2011;35:1349–58.
16. Gerszten PC, Germanwala A, Burton SA, et al., Combination kyphoplasty and radiosurgery: a new treatment paradigm for pathological fractures, *J Neurosurg Spine*, 2005;3:296–301.
17. Berenson J, Pflugmacher R, Jarzem P, et al., Balloon kyphoplasty versus non-surgical fracture management for treatment of painful vertebral body compression fractures in patients with cancer: a multicenter, randomised controlled trial, *Lancet Oncol*, 2011;12:225–35.
18. Gerszten PC, Germanwala A, Burton SA, et al., Combination kyphoplasty and spinal radiosurgery: a new treatment paradigm for pathological fractures, *J Neurosurg Spine*, 2009;3:296–301.