

The Neurogenic Component of Cutaneous Toxicities Induced by Chemotherapy—New Solutions

Jean-François Chanez, PharmD

Head, Scientific Department, Evolife Laboratoires

Abstract

Most chemotherapies cause cutaneous side effects. Docetaxel entered the therapeutic arsenal in the 1990s; while undeniably a sign of progress, it can also cause cutaneous side effects. Other chemotherapeutic drugs can induce secondary cutaneous effects, such as acneiform rash, hand-foot syndrome or mucositis. Hair loss, reversible or not, and nail disorders are also well-known deleterious effects encountered with several drugs used in oncology. Furthermore, the development of new targeted therapies is contributing to an increased frequency of these undesirable effects. New products that take into account the neurogenic phenomena implicated in the local inflammatory response to chemotherapy are required to offer new alternative care for various cutaneous and muco-cutaneous side effects.

Keywords

Neurogenic inflammation, substance P, chemotherapy, mineral elements of Evaux thermal spring water

Disclosure: Jean-François Chanez is an employee of Evolife Laboratoires.

Received: January 11, 2010 **Accepted:** October 18, 2010 **Citation:** *US Oncological Review*, 2010;6:17–9 DOI: 10.17925/OHR.2010.06.0.17

Correspondence: Shilpa Sharan, PhD, MS, Vice President, Scientific & Regulatory Affairs, PO Box 5042, NJ 08824. E: shilpas@myevolife.com; www.myevolife.com

Support: The publication of this article was funded by Evolife Laboratories.

Docetaxel is effective against numerous tumors, mainly in metastatic breast cancers; however, it can lead to other conditions, in particular cutaneous reactions, such as onycholysis and hand-foot syndrome. The unguinal toxicity of docetaxel is well-known and occurs in 40–50% of cases. The mechanism of this toxicity is of neurogenic origin. Local symptoms are due to incorrect information resulting from one or more lesions or anomalies in the nervous pathways that direct these painful nerve impulses to the sensory cerebral cortex. During large-scale release of neuromediators, particularly substance P, the inflammation becomes neurogenic. As substance P is one of the main agents implicated in inflammation of this type, any molecule preventing its release or blocking its post-synaptic action could be a potential inhibitor of this inflammation, which is deleterious to nails. Ungual side effects following chemotherapy often involve progressive destruction of the nail that can lead to intense localized pain (onycholysis). The nail may crumble or even fall off, causing problems with walking when toenails are involved or gripping difficulties when fingernails are altered. Wasner et al.¹ reported a case of a patient suffering from a cancerous tumor in the right breast, who was rendered paralyzed in the right arm following infiltration of the brachial plexus by this tumor. Treated with docetaxel, no unguinal side effects appeared on the right (paralyzed) side, while significant unguinal side effects were observed on the patient's left hand. The article underlines the neurogenic mechanism of side effects linked to chemotherapy. Substance P released under the effects of chemotherapy is described as pro-inflammatory and vasodilatory.

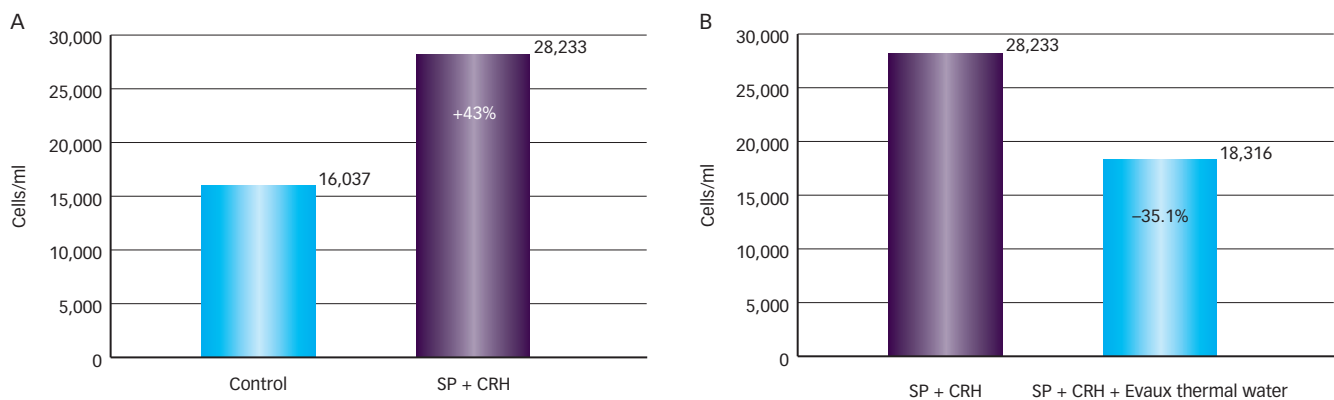
A new hydrophilic-film-forming solution containing lithium, Evonail®, acts by interfering with the signalling mechanisms determined following activation by the substance P receptors, as shown by Boisnic et al.² In this in vitro study, a human sebocyte culture model was stimulated by substance P and corticotrophin-releasing hormone (to mimic stress conditions; see Figure 1A) and the mineral constituents of Evaux thermal spring water (including lithium)—both pure and diluted by 50%—had an inhibitory effect on sebocyte proliferation (see Figure 1B). To clinically illustrate these preliminary results, some clinical case reports follow.

Case Reports

Case Report 1

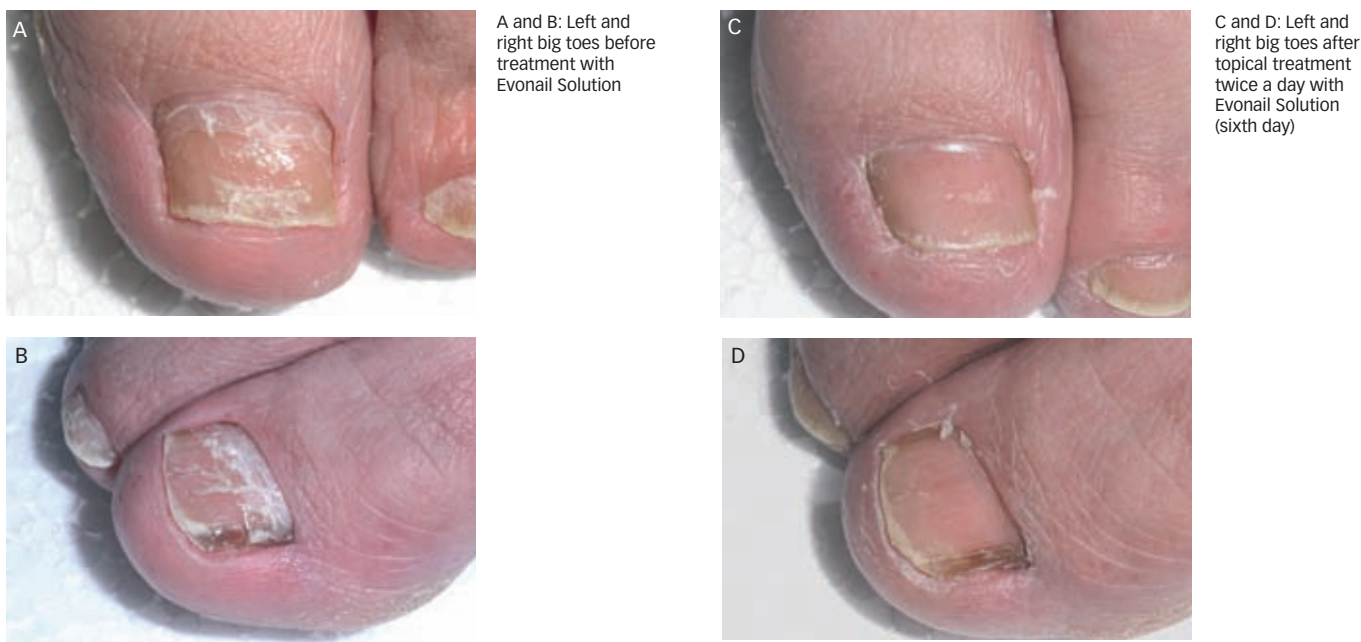
The first case report illustrates beneficial effects obtained with Evonail. A 48-year-old man presented with an acute unguinal problem. He had been treated for a metastatic colorectal cancer with irinotecan (Campto® intravenous perfusion) at a rate of two treatments per month for three years. Ungual problems had appeared six months after beginning chemotherapy. These problems resulted in onycholysis of the unguinal bed on all the nails of the fingers and toes, accompanied by intermittent unguinal hyperpigmentation of undetermined aetiology (see *Figures 2A* and *2B*). There was no prior dermatological history. Systematic cutaneous examination did not identify any particular alopecia. The patient reported cutaneous hypersensitivity and recurrent presence of ulceration of the oral mucosa. In order to reduce these unguinal symptoms, Evonail Solution was applied morning and night on all nails

Figure 1: Change in Cell Count Before and After Treatment



A: Cell count statistically increased after stimulation by substance P (SP) + corticotrophin-releasing hormone (CRH) compared with control culture. B: Cell count statistically decreased after adding Evaux thermal spring water to cell count stimulated by SP + CRH.

Figure 2: Big Toes Before and After Treatment



and their edges using an application brush. This solution leaves an invisible matt film after two to three minutes' drying time. From the sixth day after starting applications, the onycholysis was greatly reduced on all nails, and absent on some nails (see *Figures 2C* and *2D*). Only the original pigmentation persisted, although it was reduced.

The Evolife response is Evonail film-forming solution based on mineral elements contained in Evaux thermal spring water, which is presented in a 12ml glass bottle with an applicator brush. Drying time is two to three minutes (two applications per day).

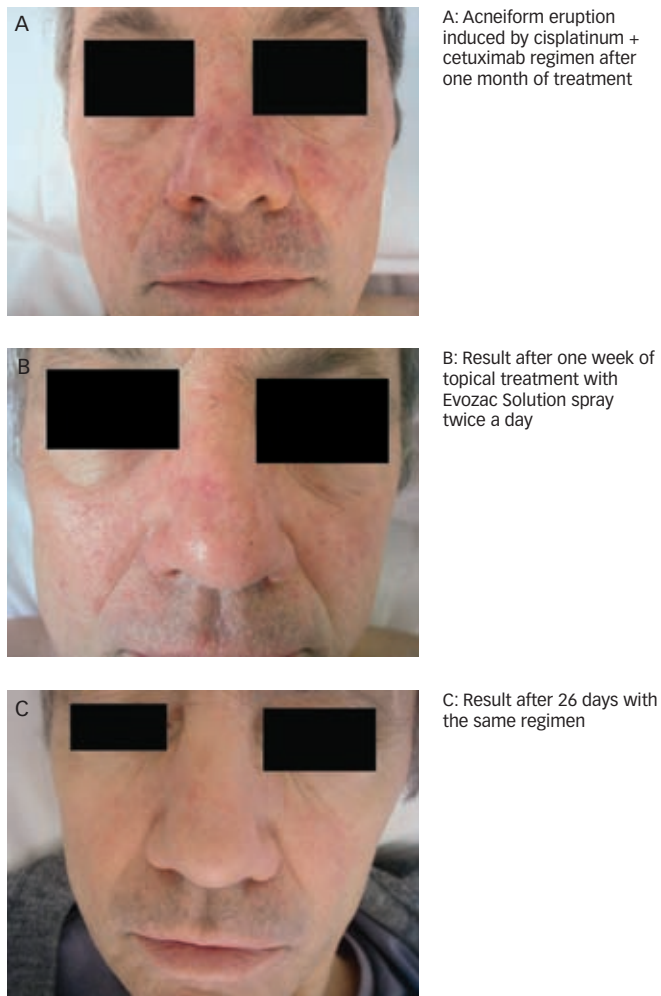Case Report 2

The second case report illustrates the acneiform rashes sometimes induced by some new targeted chemotherapies and the result obtained with the same active components formulated in a spraying solution. A 54-year-old man presented with a folliculitis-type eruption

on the face and torso against an erythematous background (see *Figure 3A*). Acneiform eruptions (folliculitis) caused by these molecules are frequently reported in the literature. He had been treated for cancer of the tongue with pulmonary metastases by the combination of cisplatin and cetuximab (Erbiximab®) for one month, after nine months of chemotherapy combining carboplatine and fluorouracil (5-FU).

In order to reduce these cutaneous symptoms, Evozac® Solution Spray was sprayed morning and night on all affected areas of the face. This solution contains neither grease nor alcohol. Evozac Solution Spray is formulated from mineral elements contained in Evaux thermal spring water (lithium, manganese, strontium). Seven days after commencing applications, the folliculitis was greatly reduced over the entire face (see *Figure 3B*). This result was maintained and improved after 26 days of applying Evozac (see *Figure 3C*). No intolerance to Evozac Solution Spray was reported by the patient during the application period.

Figure 3: Acneiform Eruption Before and After Treatment

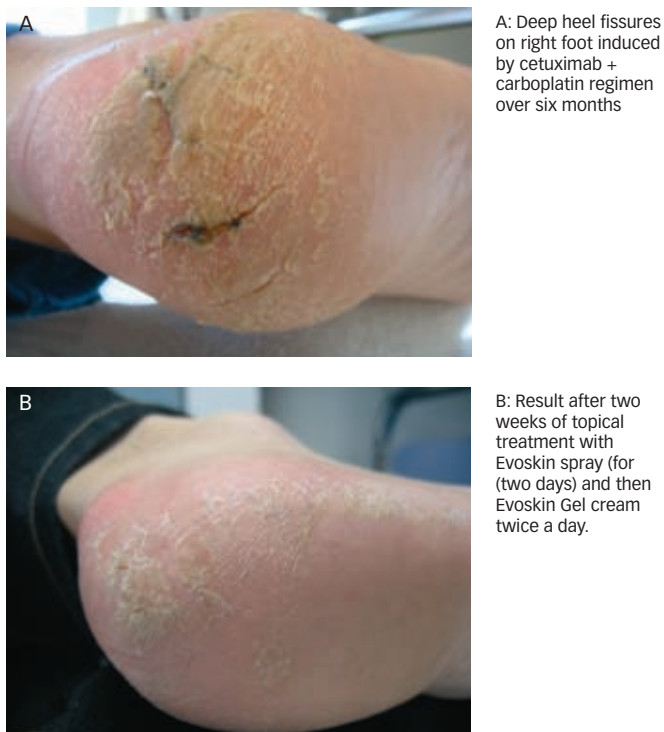

Cetuximab (Erbix), an epidermal growth factor (EGF) receptor inhibitor, is a frequently used chemotherapeutic agent, especially in the treatment of ear, nose and throat (ENT) cancers expressing this receptor. The introduction of an effective product without side effects for topical use in a rapid timespan of a few days for inflammatory lesions observed during chemotherapy offers the patient a significant functional and aesthetic benefit by improving his or her quality of life and contributing to better adherence to the chemotherapy regime.

Case Report 3

The final case report summarizes the clinical benefits obtained after using the Evoskin spray, which is specially formulated for hand-foot syndrome experienced during chemotherapy with cetuximab. A 49-year-old man presented with deep heel fissures on both feet with pronounced hyperkeratosis and significant discomfort when applying pressure to the heel (see *Figure 4A*). He had been treated for cancer of the right maxillary sinus by the combination of carboplatine and

Figure 4: Deep Heel Fissures on Right Foot Before and After Treatment



cetuximab (Erbix) for six months. In order to reduce the fissures, Evoskin Solution Spray was sprayed on the heels morning and night for the first two days, then Evoskin Gel Cream was applied as a follow-up at the same dosage. Evoskin Solution Spray and Gel Cream are formulated from mineral elements contained in Evaux thermal spring water (lithium, manganese, strontium). Two weeks after starting application of Evoskin, the fissures were closing and their haemorrhagic nature had disappeared, and the discomfort under pressure had eased (see *Figure 4B*). No intolerance to unguat Evoskin Solution Spray and Gel Cream was reported by the patient during the application period. Cetuximab (Erbix), an EGF receptor inhibitor, is a frequently used chemotherapeutic agent, especially in the treatment of ENT cancers expressing this receptor. The incapacitating fissured conditions induced by this molecule are often reported in the literature. The introduction of an effective product without side effects for topical use in a rapid timespan of several days for resolution of heel fissures observed during chemotherapy offers the patient a significant functional and aesthetic benefit by improving his or her quality of life and contributing to better adherence to the chemotherapy regimen.

Conclusion

By underlining the involvement of neuromediators in cutaneous problems, particularly following chemotherapy, Evolve Laboratories offers complete, specific and innovative solutions for cutaneous and muco-cutaneous side effects induced by chemotherapy. ■

1. Wasner G, Hilpert F, Schattschneider J, et al., *J Neur Oncol*, 2002;58:167-74. 2. Boissnic S, Branchet MC, Chanez JF, *Nouv Dermatol*, 2004;23:569-75.