

## Preventing Premature Death from Breast Cancer

a report by


**László Tabár** and **Peter B Dean**

*Medical Director, Department of Mammography, Falun Central Hospital, Sweden, and Senior Radiologist, Breast Imaging Section, Brigham and Women's Hospital, Boston, Massachusetts*

DOI: 10.17925/OHR.2006.00.00.1j



Dr László Tabár



Dr Peter B Dean

Dr László Tabár is Medical Director, Department of Mammography, Falun Central Hospital, Sweden. He is also Professor of Radiology at the University of Uppsala School of Medicine, Sweden, and Consultant Radiologist for numerous comprehensive breast centres in the US. Dr Tabár also is President of Mammography Education, Inc., Cave Creek, Arizona, and an Honorary member of the Finnish Radiology Society, the Hungarian Radiology Society and the American College of Radiology. He has authored 170 articles published in peer-reviewed medical journals. He is the recipient of the 2001 Gold Medal from the Society of Breast Imaging, among other distinguished awards.

Dr Peter B Dean is Senior Radiologist in the Breast Imaging Section at the Brigham and Women's Hospital in Boston, Massachusetts, and Visiting Professor at Harvard Medical School. He is a graduate of Harvard Medical School and holds a doctorate in medical sciences from the University of Turku, Finland, where he is Professor of Radiology. He has served as the President of the Radiological Society of Finland and is the author of more than 140 peer-reviewed publications.

Until recently, most breast cancers were detected by palpation, and were often at a late stage in their natural history when they were brought to medical attention. The outcome of these late-stage, advanced breast cancers was equally poor, regardless of the method of therapy chosen, as these large tumours were most likely associated with systemic disease. The current generation of physicians is the first to make a significant improvement in the outcome of breast cancer patients, mainly because the development of imaging methods made it possible to provide therapeutic regimens considerably earlier in the natural history of the disease. The regular use of high-quality mammography performed at sufficiently frequent intervals has brought about a shift in the balance of breast cancer cases from mainly palpable, advanced cancers to mainly small, impalpable cases that are still localised to the breast. Most clinicians are accustomed to treating tumours that are 2cm and larger; approximately 50% of these tumours are grade 3 and approximately 40% are node-positive. High-quality mammography screening detects tumours that are often 5mm to 15mm in size, of which only 20% are grade 3 and only 5% to 15% are node-positive. This predominance of early-stage disease has brought a new era in the diagnosis and treatment of breast cancer.

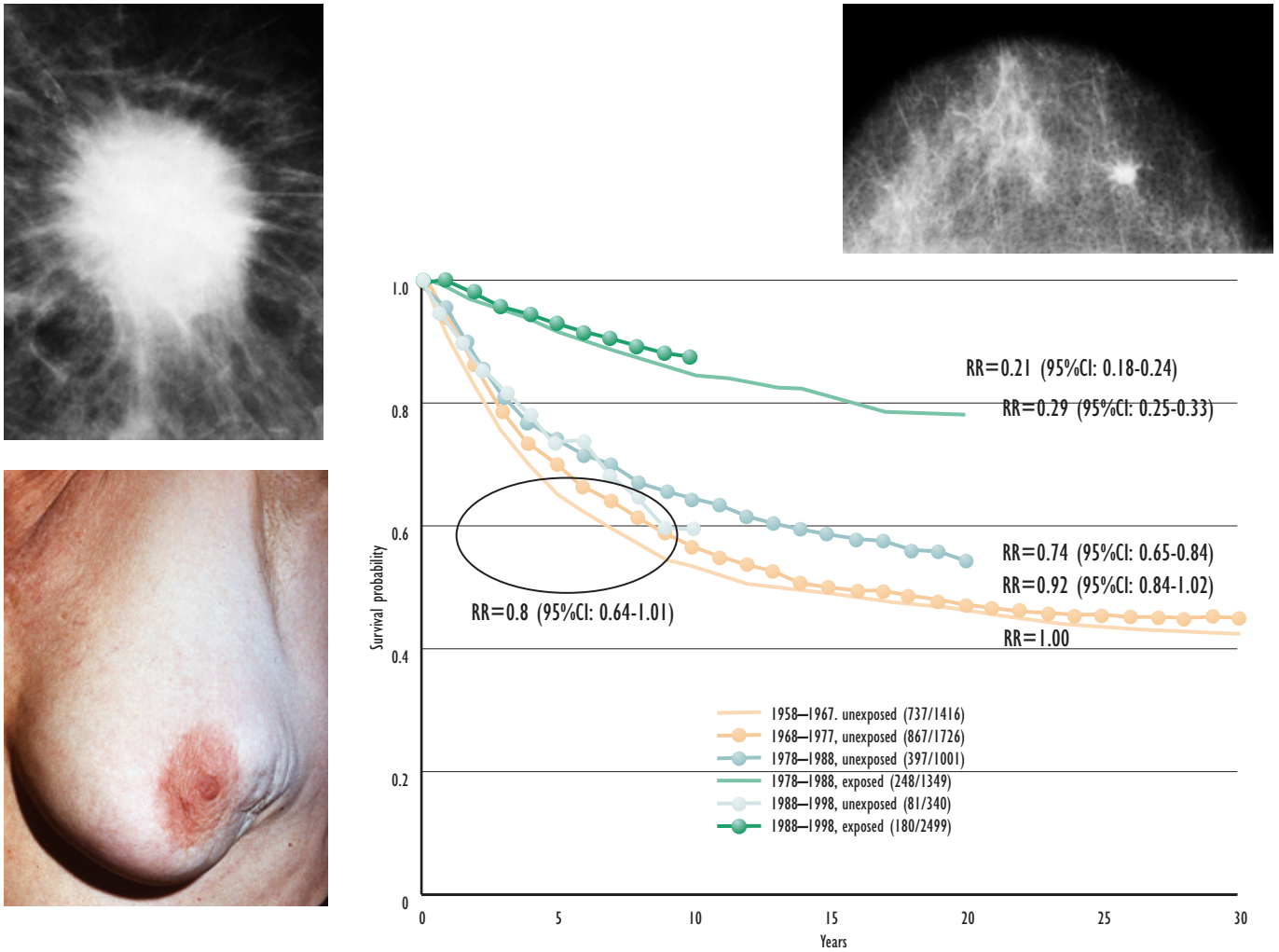
The prospective randomised controlled mammography screening trials have demonstrated that regular mammography screening could significantly reduce mortality from the disease. The beneficial effect of screening is mediated by a significant impact on all three first-generation prognostic factors – tumour size, node status and histologic malignancy grade. The tumours detected at screening are significantly smaller in size and have fewer axillary lymph node metastases. Additionally, screening can prevent worsening of the histologic malignancy grade in a certain percentage of cancers through arresting tumour growth during the pre-clinical detectable phase.<sup>1,2</sup> The significant decrease in mortality attributable to screening provides the evidence that the natural history of the disease can be altered through early detection. According to this new paradigm, breast

cancer is not a systemic disease from its inception; rather, it is a progressive disease, whose outcome can be altered by early diagnosis and treatment at an early stage.<sup>3,4</sup> This important achievement in cancer research has led to the introduction of mammography screening in many countries.

The decisive factor determining long-term outcome of breast cancer patients is whether or not the treatment is given early or late in the natural history of the disease, rather than the treatment choice that is offered to breast cancer patients. *Figure 1* demonstrates the dramatic improvement in cumulative survival of breast cancer patients brought about by the introduction of population-based mammographic screening.<sup>5</sup> During the 20-year period prior to the introduction of screening, less than half of the breast cancer cases survived the disease. The introduction of mammographic screening has led to a significant improvement in the 20-year survival of breast cancer patients who actually attended screening. However, the contemporaneous women who declined screening, but who received modern therapeutic regimens, had relatively little improvement in survival compared with the outcome of breast cancer patients diagnosed before screening was introduced. This leads to the inevitable conclusion that the prerequisite for a significant improvement in outcome from breast cancer is treatment early in its natural history, rather than treatment at a later stage.

The development of the mammographic era has had a tremendous impact on the practice of breast surgery because the tumour characteristics (size, node status and histologic malignancy grade) have changed significantly for the better. Also, the heterogeneous nature of breast cancer is more apparent in the early stages. Earlier diagnosis creates a new situation in which both the diagnostic and therapeutic team members meet problems previously seldom encountered, obligating all involved healthcare professionals to revise their diagnostic and therapeutic approaches to breast cancer. The goal is to maximise the benefits and minimise the risks by avoiding the extremes of

Figure 1: Cumulative Survival of Breast Cancer Patients in W&E Counties, Sweden



Cumulative survival of breast cancer patients in W&E counties during the 20-year screening era compared with the 20-year pre-screening era. Diagnosis at age: 40–69. The curves on top show the 10- and 20-year survival of those breast cancer patients who attended regular screening ('exposed' group) (image on right). Large, advanced breast cancers (images on left) persisted among women who did not attend screening (termed 'Unexposed') during the screening era. These women had survival curves (in light blue), which differed little from those of the prescreening era (orange), despite considerable advances in adjuvant chemotherapy.

undertreatment and overtreatment as well as the extremes of underdiagnosis and overdiagnosis. Accomplishment of this goal is no easy task; it requires new expertise and a renewed commitment.

Close co-operation among the radiologist, pathologist, surgeon, and medical and radiation oncologist has always been important in the management of breast cancer. In this new era, such close co-operation has become vital. The responsibility for diagnosis and treatment decisions has been distributed among several specialities. Comprehensive breast centres, where all specialists practice in close proximity, can most effectively meet the challenges inherent to mammographic screening. The development of new, sophisticated imaging methods in combination with interventional pre-operative biopsy procedures provide, in most cases, an accurate diagnosis with microscopic confirmation, for which the therapeutic options are many and varied. The patient is best served when a consensus decision is made by these specialists at a pre-treatment planning conference.

### T1A and T1B Tumours – The Need to Re-evaluate Tumour Classification and Treatment

The introduction of screening leads to the detection of a large number of non-palpable, T1A and T1B invasive breast cancers. In this new situation, the representatives of all specialities involved in the diagnosis and treatment of breast cancer are obliged to revise their diagnostic and therapeutic approaches to the disease. Guidelines for the treatment of breast cancer detected at screening, when the vast majority of cases are still localised to the breast, should not be based on trial results obtained on palpable, clinically diagnosed cancers. As Blake Cady has paraphrased Sir Arthur Sullivan, "Let the punishment (of treatment) fit the crime (of stage of cancer)".<sup>6</sup> Using established methods for treating palpable cancers on mammographically detected, non-palpable lesions carries a considerable risk of overtreatment.

This potential risk is demonstrated by the following study – 871 consecutive invasive breast cancers of size

1–14mm were diagnosed between 1977 and 2001 in Dalarna County, Sweden, and followed for up to 24 years. Of these, 376 were in the size category of 1–9mm, and had a 93% breast cancer-specific survival. When searching for features common to the few fatal cases, neither axillary node status or histologic malignancy grade could reliably discriminate the fatal cases from the remaining T1A and T1B cases, which had an excellent prognosis. Given that the mammographic image is a reflection of the underlying histology, an analysis of five mammographic tumour features showed them to be a highly reliable prognostic tool for predicting the long-term outcome of these early breast cancers. Half of the cases with breast cancer death shared a single, easily recognisable mammographic feature – casting-type calcifications. This subset comprising only 11% of the T1A and T1B size ranges had a 72% breast cancer-specific survival, a surprisingly poor outcome in this size range. Cases with casting-type calcifications had poor prognosis regardless of node status and histologic grade.<sup>7</sup> These results suggest that T1A and T1B tumors that are associated with casting type calcifications should belong to a more advanced-stage category, reflecting their clinical behaviour.

On the other hand, the remaining 336 cases, comprising the other four mammographic features, had an excellent, 95% 24-year disease-specific survival, irrespective of node status, histologic grade,

or mode of treatment. Stellate, 1–9mm tumours without associated calcifications comprised the largest group (50%) and had a 99% 24-year survival.<sup>7</sup> Adjuvant therapeutic regimens can offer no benefit to women with such tumours.

Given the demonstrated ability of mammography to discriminate between the high-risk and low-risk group in this size category, and the inability of other prognostic factors to predict the long-term outcome, the authors strongly recommend that the mammographic tumour features should be taken into account when planning the treatment of patients with 1–9mm breast cancers. In this study, the risk of dying from 1–9mm breast cancer was statistically significantly higher by a factor of 33 for women having tumours associated with casting-type calcifications compared with women having stellate tumours without associated calcifications.<sup>7</sup> It would therefore seem reasonable that the T1A and T1B tumour classification be revised to include the mammographic tumour features to assist in predicting long-term outcome.

Three independent studies have confirmed the prognostic value of mammographic tumour features.<sup>8–10</sup> As an ever-growing number of breast cancers are detected in the 1–14mm size range, it is imperative that the treatment be tailored accordingly. This new era calls for a new approach to diagnosis and therapy of the disease. ■

## References

1. Tabar L, Duffy S W, Vitak B, Chen H H, Prevost T C, "The natural history of breast carcinoma: what have we learned from screening?", *Cancer* (1999);Aug 1; 86 (3): pp. 449–462.
2. Tabar L, Fagerberg G, Chen H H, Duffy S W, Gad A, "Tumour development, histology and grade of breast cancers: prognosis and progression", *Int. J. Cancer* (1996);May 16; 66 (4): pp. 413–419.
3. Tubiana M, Koscielny S, "Natural history of human breast cancer: recent data and clinical implications", *Breast Cancer Res. Treat.* (1991);Aug; 18 (3): pp. 125–140.
4. Tabar L, Fagerberg G, Day N E, Duffy S W, Kitchin R M, "Breast cancer treatment and natural history: new insights from results of screening", *Lancet* (1992);Feb 15; 339 (8790): pp. 412–414.
5. Tabar L, Yen M F, Vitak B, Chen H H, Smith R A, Duffy S W, "Mammography service screening and mortality in breast cancer patients: 20-year follow-up before and after introduction of screening", *Lancet* (2003);Apr 26; 361 (9367): pp. 1,405–1,410.
6. Cady B, Keynote lecture at the Interdisciplinary Conference of Mammography Education, Inc., Scottsdale, AZ, Nov 10–13, 2004.
7. Tabar L, Tony Chen H H, Amy Yen M F, Tot T, Tung T H, Chen L S, Chiu Y H, Duffy S W, Smith R A, "Mammographic tumor features can predict long-term outcomes reliably in women with 1–14mm invasive breast carcinoma", *Cancer* (2004);Oct 15; 101 (8): pp. 1,745–1,759.
8. Thurffjell E, Thurffjell M G, Lindgren A, "Mammographic finding as a predictor of survival in 1-9 mm invasive breast cancers, worse prognosis for cases presenting as calcifications alone", *Breast Cancer Res. Treat.* (2001);67: pp. 177–180.
9. Peacock C, Given-Wilson R M, Duffy S W, "Mammographic casting type calcification associated with small screen-detected invasive breast cancers: is this a reliable prognostic indicator?", *Clin. Radiol.* (2004);59: pp. 165–170.
10. Zunzunegui R G, Chung M A, Oruwari J, Golding D, Marchant D J, Cady B, "Casting-type calcifications with invasion and high-grade ductal carcinoma in situ: a more aggressive disease?", *Arch. Surg.* (2003);138: pp. 537–540.