

Partial Splenectomy for Hereditary Spherocytosis— What Do We Know and What Do We Need to Know?

Elisabeth T Tracy, MD¹ and Henry E Rice, MD²

1. Senior Resident, General Surgery, 2. Paul H Sherman Associate Professor, and Division Chief, Pediatric Surgery, Duke University Medical Center

Abstract

Partial splenectomy is an alternative to total splenectomy for the treatment of children with hereditary spherocytosis (HS) and other congenital hemolytic anemias. Total splenectomy effectively controls the symptoms of the disease, but places children at risk for overwhelming post-splenectomy sepsis (OPSI), as well as other severe complications. A growing body of data suggests that partial splenectomy provides acceptable hematological outcomes compared with total splenectomy while preserving splenic function. In this article we briefly review the rationale for partial splenectomy, parameters to evaluate splenic function, and recent clinical data on outcomes after partial splenectomy. Although many questions remain regarding the role of partial splenectomy, it may be a promising alternative to total splenectomy in children with HS and other congenital hemolytic anemias.

Keywords

Hereditary spherocytosis, partial splenectomy, splenomegaly, congenital hemolytic anemia

Disclosure: The authors have no conflicts of interest to declare.

Received: March 16, 2009 **Accepted:** April 27, 2009 **DOI:** 10.17925/OHR.2009.02.0.9

Correspondence: Henry Rice, MD, Division of Pediatric Surgery, Box 3815, Duke University Medical Center, Durham, NC, 27710. E: rice0017@mc.duke.edu

Partial splenectomy has attracted increasing attention as an alternative to total splenectomy for the treatment of children with hereditary spherocytosis (HS) and other congenital hemolytic anemias. Total splenectomy, although quite effective for the treatment of HS, has been associated with a variety of significant complications, notably overwhelming post-splenectomy sepsis (OPSI).^{1,2} Other less recognized but potentially severe complications of splenectomy include increased risk for vascular thrombosis, vascular derangements such as hypertension and vascular disease, and various immunological impairments.³⁻⁷ Given these concerns, the use of partial splenectomy as an alternative surgical option for the treatment of HS is attractive, with the goal of providing acceptable long-term hematological outcomes as well as preserving splenic function. In this article, we discuss what is known about the efficacy and safety of partial splenectomy in the treatment of HS. We also critically examine both what is known and what is not known about the success of partial splenectomy in the preservation of splenic function in these children.

Hereditary Spherocytosis

HS is the most common inherited red blood cell (RBC) membrane disorder in Northern Europe and North America, with an incidence of one in 5,000 births. HS results from a deficiency or dysfunction of one of the constituents of the RBC cytoskeleton (most commonly ankyrin and spectrin), which leads to shortened RBC lifespan.⁸⁻¹¹ Most children with HS have a benign clinical phenotype and will not require surgical intervention; however, a subset of patients develop severe clinical sequelae of their disease, including accelerated hemolysis, hemolytic

crises, splenic sequestration, sepsis, and gallstones. These severely affected children with HS have traditionally been treated with total splenectomy, resulting in improvement of anemia, reduced rates of hemolysis, elimination of splenic sequestration, and alleviation of symptoms associated with splenomegaly.⁹

Despite the common misconception that total splenectomy is rarely employed in children with HS, the incidence and public health impact of children with HS requiring total splenectomy is substantial. The 2003 Healthcare Cost and Utilization Project (HCUP) Kids' Inpatient Database (KID), a robust and widely used measure of pediatric disorders, has estimated that the number of children 0–17 years of age with HS requiring total splenectomy is 373 children/year (HCUP Kids' Inpatient Database, ICD-9-CM category).¹²

Total Splenectomy and Splenic Function

The role of the spleen has been poorly understood for much of the history of medicine and surgery. Declared an organ unnecessary for life by Aristotle (382–322 BCE), the spleen was still considered completely expendable by Renaissance thinkers such as Andreus Vesalius (1514–1564 CE). This deeply held belief that the spleen is relatively unimportant paved the way for the first successful total splenectomy for trauma in 1678 CE by Nicholaus Matthias.¹³ Although much has been learned about the physiology of the spleen over the last few centuries, we still do not completely understand its role nor fully understand the consequences of its removal.

Table 1: Measures of Splenic Function

Clinical measures	Sepsis Other infections
Laboratory immune studies	Antibody profiles Antipneumococcal antibody
Phagocytic assays	Howell-Jolly bodies Pit count Micronuclei quantification
Radiographic	Ultrasound Doppler imaging Liver-spleen radionuclide scan
Novel measures	Memory B cells

We do know that total splenectomy puts patients at risk for the devastating complication of OPSI, characterized by multisystem organ failure following invasive infections with encapsulated bacteria such as *Streptococcus pneumoniae*. The risk for OPSI is higher for children compared with adults. For children who undergo splenectomy before five years of age, the lifetime risk for OPSI may be as high as 20%.^{1,3,5,13} Although the risk for OPSI is reduced by use of immunization against *S. pneumoniae*, *Neisseria meningitidis*, and *Hemophilus influenzae*, as well as post-operative antibiotic prophylaxis, that risk is never eliminated. As OPSI is lethal in many affected children, even this relatively small risk can be quite significant. Moreover, concerns persist regarding incomplete protection by vaccinations, antibiotic resistance, and poor compliance with antibiotic prophylaxis.^{3,14} In addition to OPSI, recent studies have suggested that the spleen may have a critically protective role in common childhood diseases. Anatomical or functional asplenia appears to lead to a high incidence of respiratory tract infections by encapsulated bacteria in children.³⁰ As infections with *S. pneumoniae* alone kill over one million children worldwide each year due to otitis media, pneumonia, and meningitis, increased susceptibility to this pathogen carries widespread public health consequences.

Our understanding of the role of the spleen in the immune response has been facilitated by the recent description of a specific B-cell subset known as immunoglobulin M (IgM) memory B cells. These cells are analogous to the murine B-1a B-cell subset that produces both natural antibodies and antibodies against T-independent (TI) antigens such as pneumococcal polysaccharides.¹⁵⁻¹⁷ Natural antibodies are primarily IgM species found independently of previous immunization that bind several antigens with low affinity and are thought to help limit infections prior to the generation of a specific antibody.^{18,19} Memory B cells are lacking in children without a spleen.^{16,17}

Interestingly, memory B cells are also lacking in children with common variable immunodeficiency (CVID), a heterogeneous immune disorder of unknown pathogenesis characterized by the inability to mount protective antibody responses in the presence of normal numbers of circulating B cells. Studies of patients with CVID have suggested that IgM memory B cells are essential for prevention and control of common childhood infections. Therefore, CVID is a model disease that suggests that the spleen may play an essential role in common childhood disease prevention through the production of memory B cells.¹⁶

Total splenectomy appears to lead to derangements in vascular homeostasis, possibly related to an increase in intravascular hemolysis

following splenectomy. Intravascular free hemoglobin reacts with nitric oxide (NO), resulting in a shift in the balance of free versus bound NO.²⁰ The clinical consequences of this altered NO balance include potential increased long-term risks of hypertension, vascular thrombosis, pulmonary hypertension, and cardiovascular disease.²⁴

Finally, total splenectomy appears to lead to an increased risk for vascular thrombosis. Although the precise mechanisms are not understood, thromboembolic events ranging from portal vein thrombosis to deep vein thrombosis and pulmonary embolism occur in up to 10% of patients who undergo total splenectomy.²⁰⁻²² With improved diagnostic modalities, the incidence of thrombosis may prove to be even higher than is now clinically appreciated. Ikeda reported that the incidence of portal or splenic vein thrombosis after laparoscopic splenectomy is 55% as determined by abdominal computed tomography (CT).²³

Partial Splenectomy and Splenic Function

Given the morbidity associated with use of total splenectomy, recently interest has grown in alternative surgical approaches for children with various clinical diseases. For children with congenital hemolytic anemias such as HS, a partial splenectomy is designed to resect enough spleen

Our understanding of the role of the spleen in the immune response has been facilitated by the recent description of a specific B-cell subset known as immunoglobulin M memory B cells.

to achieve the desired hematological effect while leaving enough remnant tissue to preserve splenic function. Based on animal models that suggest that 20% of splenic mass will preserve the splenic phagocytic response to a challenge of *S. pneumoniae*, several groups—including ours—have adopted the goal of removing 80–90% of splenic tissue for most conditions, including HS.²⁵⁻²⁷

The demonstration of preserved splenic function following partial splenectomy can be exceedingly complicated, as many different methods are used for assessing splenic function by various investigators. Methods for assessment of splenic function include clinical, laboratory, or radiographic measures (see *Table 1*). The ‘gold standard’ for evaluation of splenic phagocytic function in most pediatric hematology studies has been the liver-spleen radionuclide scan. However, other measures of splenic function include immune studies such as Ig levels, response to pneumococcal immunization, and Ig profiles following partial splenectomy. Recently, a novel and inexpensive method of assessing splenic phagocytic function based on the quantification of Howell-Jolly bodies (HJB)-containing reticulocytes and erythrocytes (micronuclei) with flow cytometry has been used. This technique is a reproducible method for quantifying chromosome fragments within circulating erythrocyte subpopulations.²⁸ This technique of micronuclei enumeration has been shown to correlate

with splenectomy status in children with sickle cell disease and is currently being used in the National Institutes of Health (NIH)-sponsored phase III infant hydroxyurea trial for children with sickle cell disease.⁴¹ Preliminary analysis suggests that flow-cytometry-based enumeration of HJB is similar to other traditional measures of splenic function, including the liver–spleen scan.²⁹ Finally, as discussed previously, analysis of memory B cells (IgM^{bright}IgD^{dull}CD22⁺CD27⁺) may afford a highly specific method of confirming the preservation of splenic immune function following partial splenectomy.

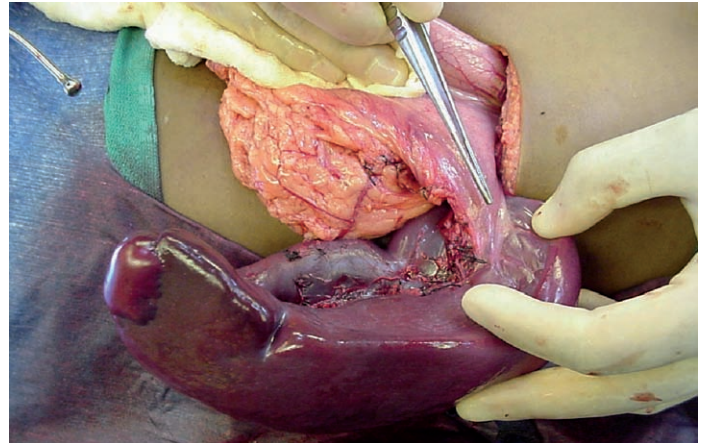
Partial Splenectomy in Children with Hereditary Spherocytosis

Several reports from small, non-randomized trials from Europe and North America suggest that partial splenectomy provides an excellent hematological outcome as well as preserved splenic function in children with HS.^{7,30–35} The resurgence of interest in the use of partial splenectomy for HS has been credited to Tchernia and colleagues from France.^{2,7,30} This group has reported a sustained decrease in hemolysis and an improvement in control of anemia in most children. In their most recent summary of 40 children one to 14 years of age, the mean hemoglobin level increased from 9.2±2.6g/dl at baseline to 12.3±1.9g/dl three to four years after surgery (p<0.01), with similar hemoglobin levels maintained for up to 10 years after surgery. Also, this group demonstrated preserved phagocytic function of the splenic remnant using radionuclide liver–spleen scan in most children.

Similarly, a group in the Czech Republic has published their experience with 14 children with HS undergoing partial splenectomy.³⁶ In this non-randomized study, mean hemoglobin levels increased from 9.9 to 13.8g/dl. At five-year follow-up, no child required late conversion to total splenectomy. Additionally, Vasilescu et al. from Romania reported excellent results in a non-randomized group of children with HS undergoing laparoscopic partial splenectomy, suggesting that a laparoscopic approach may provide acceptable clinical results using a minimally invasive technique.³⁹

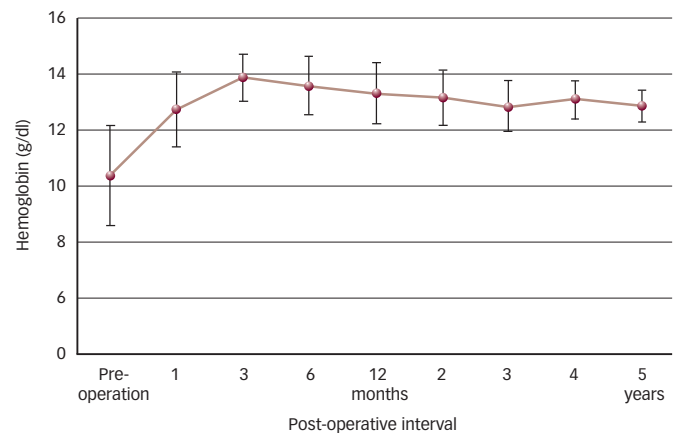
A more radical approach to partial splenectomy in HS has been advocated by Stoehr et al. from Germany.^{34,35} In response to the concerns of persistent hemolysis following partial splenectomy, as noted in the French experience as well as in our observations, Stoehr et

Figure 1: Intraoperative Photograph of the Spleen After Selective Devascularization of Lower Pole and Main Body



Upper pole remains perfused from short gastric vessels, allowing for resection of 85% of the splenic parenchyma.

Figure 2: Mean Hemoglobin Levels After Partial Splenectomy



Graph represents 12 children with hereditary spherocytosis who most recently underwent partial splenectomy at Duke University. Hemoglobin levels increased compared with pre-operative values throughout four to six years of follow-up (p<0.05 by paired Student t-test). Error bars show standard deviation.

2.9–5g/dl and bilirubin decreased by 15.4–56.4μmol/l. Although an NTS appears to result in improved hemolysis compared with baseline, preserved splenic function has not been clearly demonstrated in their experience and is a point of concern for many clinicians.

Several groups in North America have begun to examine the role of partial splenectomy in children with HS (see Figure 1).^{32,33,37,40} Our group, in collaboration with the Children’s Hospital of Wisconsin, has a combined experience of partial splenectomy in over 60 children with HS.^{33,37} In our initial experience, we observed that mean hemoglobin levels increase by 2–3gm/dl compared with baseline at three months following surgery, a difference that persisted over 10 years of follow-up (p<0.05) (see Figure 2).^{33,37} We also observed sustained control of hemolysis, as reticulocyte counts decreased from 12.7±4.2% pre-operatively to 4.9±2.9% (mean ± standard deviation [SD]; p<0.05). Mean serum bilirubin levels decreased from a level of 2.6±1.1mg/dl pre-operatively to 1.3±0.7mg/dl (mean ± SD; p<0.05).

The demonstration of preserved splenic function following partial splenectomy can be exceedingly complicated, as many different methods are used for assessing splenic function by various investigators.

al. have advocated a more radical spleen resection. This technique has been termed a near-total splenectomy (NTS), and is designed to preserve a residual spleen volume of around 10cm³, the equivalent of a 98% extent of resection. In their most recent summary, 30 children with HS received an NTS. At follow-up, mean hemoglobin level increased by

We have also noted that following partial splenectomy, splenic phagocytic function is preserved by the clearance of HJB. Interestingly, during the first month post-operatively, many children have detectable circulating HJB in the peripheral smear. However, this finding is transient, and only one child in our experience had detectable HJB during any future exam. Five children were tested post-operatively for pitted RBCs using Nomarski optics; three had normal levels (<2%) and two children had mildly elevated levels (3–6%). Preservation of many aspects of normal immune function was also observed among our patients who underwent partial splenectomy, consistent with the French experience. At our center, seven children were tested at three years for Ig production, with maintenance of normal levels of IgG and IgM (IgG 977 ± 266 mg/dl at baseline and $1,193 \pm 405$ mg/dl at three years after surgery; IgM 99 ± 32 mg/dl at baseline and 89 ± 33 mg/dl at three years after surgery). Five of six children retained normal specific antibody titers to *S. pneumoniae*. Importantly, no child has developed severe post-operative infection or sepsis. In summary, in our experience, as well as that of the French group, there appears to be preservation of many measures of splenic phagocytic response and various measures of an immune response following partial splenectomy.

Although there is little experience in quantifying IgM memory B cells following partial splenectomy, we examined these cells in one child with HS four weeks after partial splenectomy. In this single child, we found the frequency of IgM^{bright}IgD^{dull}CD22⁺CD27⁺ IgM memory B cells to be 19% of CD22⁺CD27⁺ cells, suggesting that these cells can be preserved following partial splenectomy, at least in short-term follow-up.^{16,17} Given the previously published data on the absence of these cells in children following total splenectomy,³⁰ these preliminary observations suggest that the retention of memory B cells following partial splenectomy may be feasible and warrants further study.

Concerns Regarding Partial Splenectomy

One concern often raised regarding partial splenectomy is that of re-growth of the splenic remnant. In the clinical studies to date, there has been variable splenic re-growth after partial splenectomy in some children as measured by sonographic measurement of splenic volume. In our experience, re-growth is initially slow, as the size of the splenic remnant remained between 15 and 30% of baseline volume throughout the first two years of follow-up, significantly below the pre-operative size ($p < 0.05$). By four-year follow-up, the splenic re-growth was more pronounced, averaging 40% of original splenic size, although the rate of splenic re-growth is quite variable among children. Interestingly, in our

experience, re-growth of the spleen did not appear to be associated with recurrent hemolysis, an observation also noted in the French experience.

One additional concern regarding partial splenectomy has been the feasibility of this approach in the setting of massive splenomegaly. Although there are few published studies of partial splenectomy in this setting, we compared children with various congenital hemolytic anemias both with and without massive splenomegaly (defined as measured splenic volume >500ml) who underwent the procedure. We found that children both with and without massive splenomegaly had successful outcomes from partial splenectomy. Both groups demonstrated decreased transfusion requirements, increased hematocrit, decreased bilirubin levels, decreased reticulocyte counts, and elimination of splenic sequestration.^{16,17}

Conclusion

A small but growing body of evidence suggests that partial splenectomy offers an acceptable hematological outcome while preserving splenic function in children with HS; however, many questions remain. Partial splenectomy seems to preserve many measures of an immune response, but are these measures specifically related to the preservation of splenic function? Can novel specific measures such as the memory B cells confirm the preservation of splenic function following partial splenectomy? Is there a demonstrable clinical benefit for children undergoing partial splenectomy compared with total splenectomy? Can a partial splenectomy decrease the long-term risks of altered vascular homeostasis, such as hypertension and vascular disease? Both time and experience will be needed to fully answer these many important questions. ■



Elisabeth T Tracy, MD, is a Senior Resident in General Surgery at Duke University Medical Center. She hopes to pursue a fellowship in pediatric surgery after completing her general surgery residency. Dr Tracy received her bachelor's degree from Harvard University and her MD from Harvard Medical School.



Henry E Rice, MD, is the Paul H Sherman Associate Professor and Division Chief of Pediatric Surgery at Duke University Medical Center. His clinical and research interests include treatment of congenital malformations, pediatric oncology, and thoracic and abdominal surgery. One of his main clinical interests is the surgical management of congenital hemolytic anemias, and he is considered a leader in the study of partial splenectomy in children.

- King H, Shumacker HB Jr, *Ann Surg*, 1952;136(2):239–42.
- Tchernia G, et al., *Curr Opin Hematol*, 1997;4(2):136–41.
- Brigden ML, Pattullo AL, *Crit Care Med*, 1999;27(4):836–42.
- Green JB, et al., *J Trauma*, 1986;26(11):999–1004.
- Lynch AM, Kapila R, *Infect Dis Clin North Am*, 1996;10(4):693–707.
- Styrt B, *Am J Med*, 1990;88(5N):33N–42N.
- Tchernia G, et al., *Blood*, 1993;81(8):2014–20.
- Bolton-Maggs PH, et al., *Br J Haematol*, 2004;126(4):455–74.
- Delaunay J, *Crit Rev Oncol Hematol*, 1995;19(2):79–110.
- Edelman EJ, et al., *Blood*, 2007;109(12):5491–3.
- Tse WT, Lux SE, *Br J Haematol*, 1999;104(1):2–13.
- Quality, A.f.H.R.a., HCUP Kids' Inpatient Database, 2003.
- Upadhyaya P, *Pediatr Surg Int*, 2003;19(9–10):617–27.
- Gold HS, Moellering RC Jr, *N Engl J Med*, 1996;335(19):1445–53.
- Forster I, Rajewsky K, *Eur J Immunol*, 1987;17(4):521–8.
- Kruetzmann S, et al., *J Exp Med*, 2003;197(7):939–45.
- Weller S, et al., *Blood*, 2004; 104(12):3647–54.
- Ochsenbein AF, et al., *Science*, 1999;286(5447):2156–9.
- Ochsenbein AF, Zinkernagel RM, *Immunol Today*, 2000;21(12):624–30.
- Rother RP, et al., *JAMA*, 2005;293(13):1653–62.
- Cappellini MD, et al., *Ann N Y Acad Sci*, 2005;1054:317–24.
- Mohren M, et al., *Am J Hematol*, 2004;76(2):143–7.
- Ikeda M, et al., *Ann Surg*, 2005;241(2):208–16.
- Hoeper MM, et al., *Ann Intern Med*, 1999;130(6):506–9.
- Goldthorn JF, et al., *J Pediatr Surg*, 1978;13(6D):587–90.
- Malangoni MA, et al., *Arch Surg*, 1985;120(3):275–8.
- Witte MH, et al., *Lymphology*, 1983;16(2):128–37.
- Dertinger SD, et al., *Mutat Res*, 2003;542(1–2):77–87.
- Rogers ZEA, *Blood*, 2004;104: abstract 975a.
- Bader-Meunier B, et al., *Blood*, 2001;97(2):399–403.
- Dutta S, et al., *Surg Endosc*, 2006;20(11):1719–24.
- Freud E, et al., *Blood Cells Mol Dis*, 1998;24(3):309–16.
- Rice HE, et al., *Ann Surg*, 2003;237(2):281–8.
- Stoehr GA, et al., *Br J Haematol*, 2006;132(6):791–3.
- Stoehr GA, et al., *Ann Surg*, 2005;241(1):40–47.
- Jabali T, et al., *Haematologica*, 2007;92(Suppl. 1):289 (abstract).
- Diesen DL, et al., *J Pediatr Surg*, 2008;43(3):466–72.
- Tracy ET, Rice HE, *Pediatr Clin North Am*, 2008;55(2): 503–19.
- Vasilescu C, et al., *Surg Endosc*, 2006;20(5):748–52.
- Hall JG, et al., *J Pediatr Surg*, 2005; 40(1):221–7.