

## Antibody–Drug Conjugates in Relapsed/Refractory CD30-positive Lymphomas

Ulrich Jager<sup>1</sup> and Martin Hutchings<sup>2</sup>

1. Professor of Hematology, Medical University of Vienna, Vienna, Austria; Head of the Clinical Department of Hematology and Hemostasis at Vienna General Hospital, Vienna, Austria; 2. Clinical Oncologist, Department of Hematology, Rigshospitalet, Copenhagen, Denmark

### Abstract

Although chemotherapy and radiotherapy are associated with good outcomes in patients with advanced Hodgkin's lymphoma (HL) and systemic anaplastic large cell lymphoma (sALCL), there is a need for alternative approaches to maximise control of the lymphoma in refractory and relapsed cases. Antibody–drug conjugates (ADCs) allow specific targeting of drugs to neoplastic cells. The ADC brentuximab vedotin (BV) has the ability to target cluster of differentiation (CD) 30+ tumour cells and initiate cytotoxic effects. In two phase II trials, BV resulted in objective responses in 75 % and 86 % of patients with refractory or relapsed HL and sALCL, respectively, with an acceptable toxicity profile. Based on these data, BV was granted accelerated approval by the US Food and Drug Administration for the treatment of refractory and relapsed HL and ALCL. A promising indication for BV is acting as a bridge to stem cell transplantation (SCT). Numerous studies are currently examining the role of BV as salvage therapy prior to autologous or allogeneic SCT, as well as in other clinical settings.

### Keywords

Antibody–drug conjugates, brentuximab vedotin, Hodgkin's lymphoma, systemic anaplastic large cell lymphoma

**Disclosure:** Ulrich Jager has received honoraria and participated in Advisory Boards for Takeda. Martin Hutchings has participated in Advisory Boards for Celgene, Genentech, Janssen and Takeda, and has been a consultant to Genentech and Takeda.

**Acknowledgements:** Medical writing assistance was provided by Katrina Mountfort at Touch Medical Media and funded by Takeda.

**Open Access:** This article is published under the Creative Commons Attribution Noncommercial License, which permits any non-commercial use, distribution, adaptation and reproduction provided the original author(s) and source are given appropriate credit.

**Received:** 23 June 2015 **Accepted:** 3 September 2015 **Citation:** *European Oncology & Haematology*, 2015;11(2):Epub ahead of print

**Correspondence:** Ulrich Jager, Medical University of Vienna, Vienna, Spitalgasse 23, 1090 Wien, Austria. E: ulrich.jaeger@meduniwien.ac.at  
Martin Hutchings, Department of Haematology, Rigshospitalet, 9 Blegdamsvej, 2100, Copenhagen, Denmark. E: martin.hutchings@gmail.com

**Support:** The publication of this article was supported by Takeda, who were given the opportunity to review the article for scientific accuracy before submission. Any resulting changes were made at the author's discretion.

Antibody-based therapeutics have become an essential component of cancer therapy since the introduction of rituximab in the late 1990s. However, although they can confer clinical benefits, especially when combined with chemotherapy, many monoclonal antibodies do not provide long-term beneficial effects.<sup>1</sup> There is therefore a need to improve the therapeutic efficiency of monoclonal antibodies. Antibody–drug conjugates (ADCs) allow the linking of potent cytotoxic drugs to tumour antigen-specific antibodies, enabling specific targeting of drugs to neoplastic cells while minimising systemic toxicity. ADCs are becoming an increasingly important subclass of antibody-based therapeutics, with 35 ADCs in clinical development in November 2013.<sup>2</sup>

Cluster of differentiation (CD) 30 is a transmembrane cytokine receptor protein expressed on certain neoplasms but not normal cells, making it a promising target for therapeutic intervention. Two aggressive lymphoid neoplasms are characterised by strong and uniform expression of CD30: Hodgkin's lymphoma (HL) and systemic anaplastic large cell lymphoma (sALCL). Early studies of anti-CD30 monoclonal antibodies were promising, although the antibodies had only modest activity as single-agent therapy,<sup>3,4</sup> leading to the development of the anti-CD30 ADC, brentuximab vedotin (BV, Adcetris®).

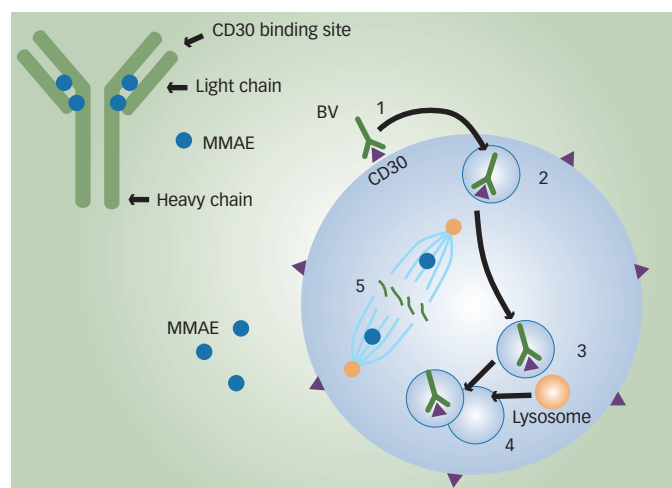
This review will focus on the unmet needs in the management of HL and sALCL and discuss clinical studies investigating the efficacy and safety of BV.

### Current Standard of Care in Hodgkin's Lymphoma and Systemic Anaplastic Large Cell Lymphoma

HL is characterised by the orderly spread of disease from one lymph node to the other. Systemic symptoms are associated with advanced disease. The incidence of HL shows a bimodal age distribution, with the first peak in incidence rates in young adults, and the second peak in older people.<sup>5</sup> It is the most common malignancy in adolescents.<sup>6</sup>

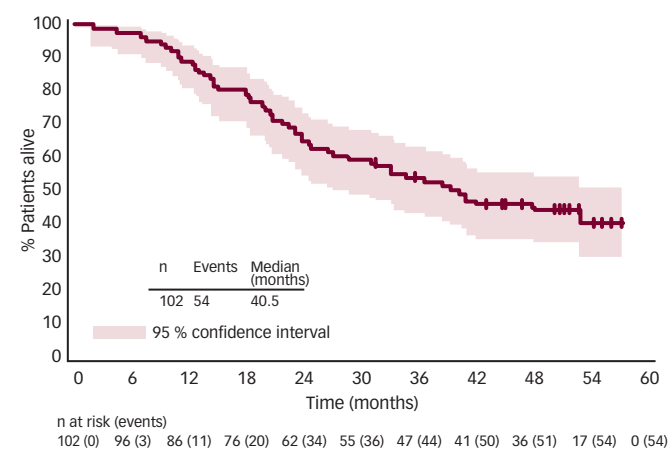
Despite the fact that first-line combined chemotherapy regimens, including doxorubicin (Adriamycin), bleomycin, vinblastine and dacarbazine (ABVD), achieve durable remission rates in approximately 80 % of cases,<sup>7</sup> a substantial proportion of patients with advanced HL (20–30 %) are refractory to therapy or relapse after initial treatment.<sup>8</sup> Remission rates can be increased by around 10 % with the use of more intensive chemotherapy regimens such as bleomycin, etoposide, doxorubicin, cyclophosphamide, vincristine, procarbazine and prednisone (BEACOPP), but this treatment carries the risk of serious adverse events (AEs).<sup>9,10</sup>

**Figure 1: Mechanism of Action of Brentuximab Vedotin**



1. Brentuximab vedotin (BV) binds to cluster of differentiation (CD) 30 on target cell surface; 2. Bound BV is internalised by clathrin-mediated endocytosis; 3. Within the cytoplasm, the clathrin-coated vesicle is stripped of clathrin; 4. The vesicle is joined to a lysosome that releases cathepsin, yielding free monomethyl auristatin E (MMAE); 5. MMAE inhibits tubulin polymerisation and arrests growth. Adapted from Chen, 2013 and Katz, 2011.<sup>84,85</sup>

**Figure 2: Progression-free Survival Achieved with Brentuximab Vedotin in a Phase II Study of Hodgkin's Lymphoma Compared with Progression-free Survival Achieved with the Last Therapy**



Reproduced with permission from Gopal et al., 2015.<sup>35</sup>

Relapsed or refractory HL can be treated by salvage chemotherapy based upon either ifosfamide (with carboplatin and etoposide [ICE] or etoposide and epirubicin [IVE]), gemcitabine (with dexamethasone and cisplatin [GDP] or with vinorelbine and doxorubicin [GND]) or platinum (with dexamethasone and cytarabine [DHAP] or etoposide, methylprednisolone and cytarabine [ESHAP]) and, if chemosensitive, are subsequently treated with high-dose chemotherapy and autologous stem cell transplantation (auto-SCT), which has a 5-year time-to-treatment failure (TTF) and overall survival (OS) of around 50%.<sup>11-14</sup> Normalisation of 18-fluorodeoxyglucose-positron emission tomography (FDG-PET) imaging prior to ASCT has been associated with improved outcomes.<sup>15</sup> For patients who experience relapse after auto-SCT, the prognosis is poor: median survival time is approximately 2 years.<sup>11</sup> Until recently, there has been no standard of care for patients with relapsed/refractory HL after failure of auto-SCT. Options include palliative

chemotherapy or reduced-intensity allogeneic SCT (allo-SCT). The use of allo-SCT is controversial, with disease relapse and progression reported in more than half of patients.<sup>16-18</sup> Following the failure of allo-SCT, treatment options are limited and the prognosis for patients at this stage is extremely poor.<sup>19</sup> There is therefore a need for new therapeutic options for HL patients with relapsed/refractory disease.

SALCL is a rare type of non-HL (NHL), and represents a group of large cell lymphomas, distinguished from other lymphomas by its anaplastic cytology and constant membrane expression of the CD30 antigen.<sup>20</sup> It is a T-cell lymphoma comprising about 3 to 8% of all NHLs in adults and 10 to 15% of all NHLs in children.<sup>21,22</sup> There are two subtypes of sALCL: primary systemic anaplastic lymphoma kinase (ALK)+ ALCL and primary systemic ALK- ALCL.<sup>20</sup> Primary cutaneous ALCL also exists, but this is a separate disease entity and is localised to the skin.

First-line therapy for sALCL is typically a combined chemotherapy regimen such as cyclophosphamide, doxorubicin, vincristine and prednisone (CHOP). Overall responses of 86% and 68% have been reported in ALK+ and ALK- ALCL, respectively.<sup>23</sup> ALK+ ALCL predominantly affects young male patients and responds well to chemotherapy.<sup>24</sup> sALCL in paediatric and adolescent patients has a relapse rate of 25-30%. ALK- ALCL occurs in older patients, affecting both genders equally and is associated with low response rates to chemotherapy: up to 60% of patients may relapse after first-line therapy.<sup>20</sup> The therapies for refractory or relapsed disease are highly variable, ranging from single-agent chemotherapy to allo-SCT, with some success, but no established standard. An oral ALK tyrosine kinase inhibitor is in early-stage clinical development,<sup>25</sup> and platelet-derived growth factor receptor- $\beta$  (PDGFR) blockade with imatinib has also been effective in single cases.<sup>26</sup>

However, until recently, there was no standard of care for these patients with HL and sALCL. Given the young age of many patients, the management of these lymphomas represents an important unmet clinical need.

## Anti-CD30 Antibody-Drug Conjugates – Brentuximab Vedotin

Brentuximab vedotin is an ADC composed of the monoclonal antibody cAC10, which targets the CD30 antigen on HL and sALCL cells; a highly stable valine-citrulline linker; and a potent antimetabolic agent: monomethyl auristatin E (MMAE), connected by a protease-cleavable valine-citrulline dipeptide linker. Its mechanism of action is illustrated in Figure 1. Binding of the ADC to CD30 on the cell surface leads to internalisation of the CD30-ADC, the result of clathrin-mediated uptake. Once inside the cytoplasm, the vesicle joins to a lysosomal vesicle containing proteolytic enzymes, which then releases MMAE into the tumour microenvironment.<sup>27</sup> The free MMAE blocks the polymerisation of tubulin, resulting in G2/M phase growth arrest and apoptotic death.<sup>28</sup> In addition, MMAE accumulates in the extracellular space due to its membrane permeability and has potential cytotoxic effects on surrounding CD30-negative bystander cells.<sup>29</sup>

In addition to its effect on MMAE activity, treatment with BV induces the release of cytokines such as interleukin-6, chemokine ligand 17 and tumour necrosis factor  $\alpha$ .<sup>30</sup> Another potential mechanism of action is interruption of CD30/CD30 ligand interaction. The CD30 ligand (CD153) present on bystander cells may regulate tumour cell proliferation.<sup>31</sup> By interfering with this interaction, BV may inhibit tumour growth.

Treatment with BV may also focus the HL-specific immune response against the tumour as a result of the release of tumour antigens and proinflammatory modulation of the tumour microenvironment.<sup>32</sup>

**Clinical Studies Investigating the Efficacy of Brentuximab Vedotin in Hodgkin’s Lymphoma and Systemic Anaplastic Large Cell Lymphoma in Different Clinical Settings**

**Relapsed/Refractory Hodgkin’s Lymphoma and Systemic Anaplastic Large Cell Lymphoma**

A summary of clinical studies investigating the efficacy and safety of BV in HL and sALCL can be found in Table 1. Two pivotal phase II studies have demonstrated the efficacy and safety of BV in relapsed/refractory HL and sALCL. In a phase II study of BV in patients with relapsed/refractory HL (n=102), the overall response rate (ORR) was 75 % with complete remission (CR) in 34 % of patients.<sup>33</sup> In 3-year follow-up data, patients achieved a median OS of 40.5 months with BV (see Figure 2). Overall, patients received a median of nine cycles (range 1–16) and patients who achieved an objective response received more cycles of therapy.<sup>34</sup> Recent follow-up data show that 47 % of patients who achieved CR on BV remain progression-free after a median 53 months. Younger age, less functional impairment and lower disease burden at baseline were associated with CR and longer survival.<sup>35</sup>

In a phase II study of BV in patients (n=58) with relapsed/refractory sALCL, the ORR was 86 %, CR in 57 % and partial remission (PR) in 29 %.<sup>36</sup> At 3-year follow-up, the median duration of objective response for all patients was 13.2 months; and for patients obtaining a complete response (CR) the median duration of response was 26.3 months. Of the patients who achieved a CR, 47 % remained in remission at the time of analysis. The estimated 3-year survival rate was 63 %, while the median OS for patients obtaining a CR had not been reached.<sup>37</sup> Recently presented data showed that the 4-year survival rate was 64 %. Of the 47 % patients with CR at 3 years, all remained in remission with no evidence of progression, suggesting that BV treatment may be curative for some patients (see Figure 3).<sup>38</sup>

On the basis of these data, the US Food and Drug Administration (FDA) granted accelerated approval to BV for the treatment of patients with HL after failure of auto-SCT or after failure of at least two prior combined chemotherapy regimens in patients who are not auto-SCT candidates, and for the treatment of patients with sALCL after failure of at least one prior combined chemotherapy regimen.<sup>39</sup>

A study was also initiated to investigate if patients (21 with HL; eight with sALCL) who had previously responded to BV could achieve another remission with retreatment.<sup>40</sup> The ORR was 60 % (30 % CR) in HL patients and 88 % (63 % CR) in sALCL patients. The estimated median duration of response for patients with an objective response was 9.5 months at study completion. Of the 19 patients with objective response, seven patients had not had an event of disease progression or death at the time of study completion; duration of response for these patients ranged from 3.5 to 28 months. Of the 11 patients with CR, 45 % had response durations of over 1 year. The study concluded that retreatment with BV was safe and feasible.<sup>40</sup>

A number of studies detailing the use of BV on named patient programmes have been published. Clinical outcomes in these ‘real use’ studies have been similar to those reported in the phase II clinical trials<sup>41–44</sup> and have enabled patients to progress to auto-SCT or allo-SCT.

**Table 1: Summary of Clinical Studies Investigating the Efficacy and Safety of Brentuximab Vedotin in HL and sALCL**

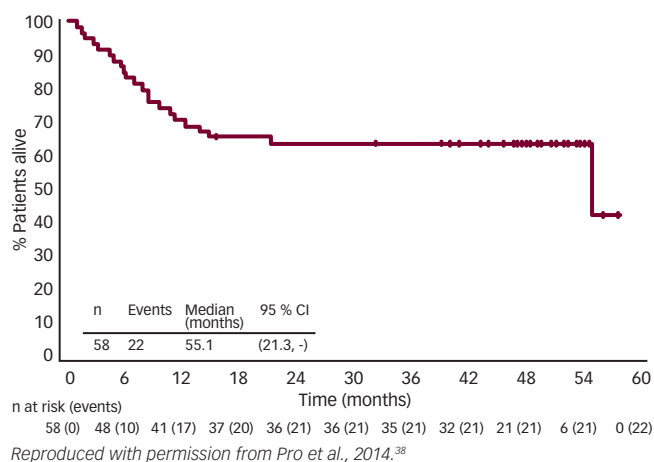
Treatment Setting	Trial Type	Results	Reference
Relapsed/refractory HL	Phase II, n=102,	ORR = 75 % CR in 34 % OS = 40.5 months	33,34
Relapsed/refractory sALCL	Phase II, n=58	ORR = 85 % CR in 57 %, PR in 29 % 3-year survival = 63 %	36,37
Relapsed, refractory HL/sALCL, previous treatment with BV	n=21 with HL and 8 with sALCL	ORR = 60 % CR in 63 %	40
Relapsed/refractory HL, transplant-naïve	Retrospective study, n=14	ORR = 71 %, CR in 36 % allowed SCT in 35.7 %	42
Relapsed/refractory HL with ≥1 treatment failure on prior regimen	Phase II, n=40	CR = 80 %, 97.55 % eligible for auto-SCT, 30 % avoided ICE salvage therapy	83
Relapsed/refractory HL, patients undergoing allo-SCT	n=27, 14 received BV prior to allo-SCT, in 7 BV was last therapy prior to SCT	ORR prior to allo-SCT 79 % in BV treated versus 46 % in BV naïve; p=0.12 CR = 100 % in patients who received BV as last therapy prior to SCT	54
Relapsed/refractory HL, patients >100 days after alloSCT	n=25	ORR = 50 %, CR in 38 % PF = 7.8 months	55
Treatment-naïve patients with classical HL (stage I–IV)	Phase II, n=13 to date	Of 11 assessed patients, ORR = 82 % CR = 64 %	56
Treatment-naïve patients with advanced HL, with ABVD or AVD	Phase I/II	Pulmonary toxicity in 44 % with ABVD, well-tolerated with AVD	57
Treatment-naïve patients with advanced HL, with a modified BEACOPP	Phase II, n=48	Appears feasible without compromising the efficacy associated with escalated BEACOPP	58

ABVD = doxorubicin (Adriamycin), bleomycin, vinblastine and dacarbazine; AVD = doxorubicin (Adriamycin), vinblastine and dacarbazine; BEACOPP = bleomycin, etoposide, doxorubicin, cyclophosphamide, vincristine, procarbazine and prednisone; BV = brentuximab vedotin; CR = complete response; HL = Hodgkin’s lymphoma; ORR = overall response rate; OS = overall survival; sALCL = systemic anaplastic large cell lymphoma; SCT = stem cell transplantation.

In a randomised, double-blind, placebo-controlled, multicentre phase III study to evaluate the efficacy and safety of BV and best supportive care (BSC) versus placebo and BSC in patients at high risk of residual HL after auto-SCT (the AETHERA trial), a total of 329 patients were enrolled in one of three high-risk categories: refractory to frontline therapy (59.6 %); relapse <12 months after frontline therapy (32.7 %); and relapse ≥12 months after frontline therapy with extranodal disease (7.6 %). The estimated 2-year PFS rate was 54 % and the estimated 2-year OS rate was 88 %.<sup>45</sup>

In a recent systematic review of six published prospective studies (n=302) of BV in relapsed/refractory HL and sALCL, meta-analyses were carried out to calculate the objective response rate (ORR), complete response rate (CRR) and partial response rate (PRR), and

**Figure 3: Overall Survival – 4-year Data from a Phase II Study of Systemic Anaplastic Large Cell Lymphoma**



found an ORR of 0.61, CRR of 0.38 and PRR of 0.25. High heterogeneity between the studies was found; however, the definition of relapsed/refractory differed between investigators. The study concluded that BV demonstrated promising benefit but that larger study populations were needed in future.<sup>46</sup> Another meta-analysis compared data from a phase II study of BV33 (n=102) with data from 17 historical studies (n=802) in patients with relapsed/refractory HL post-auto-SCT. The CR for BV (34 %) exceeded the estimated overall CR of the historical data (11.1 %).<sup>47</sup>

### Brentuximab Vedotin as Salvage Therapy and as a Bridge to Stem Cell Transplantation

Based on the encouraging results from phase II studies, BV is currently being investigated in different disease settings. BV has been associated with manageable AEs in transplant-naïve patients with relapsed or refractory HL (the majority were chemorefractive), demonstrating that its antitumor activity is not limited to patients who received BV after auto-SCT.<sup>48</sup> BV may therefore be used as a bridge to transplantation in patients who might not otherwise fulfil the criteria for autologous transplant intervention. A retrospective study examined data from 14 patients with refractory or relapsed HL who were treated with BV as single agent in a named patient programme, and had not received prior high-dose chemotherapy and auto-SCT due to refractory disease (n=9), comorbidity (n=4) and unknown reasons (n=1). In these patients, BV resulted in an ORR of 71 % with CR in 36 %, and allowed consolidating auto-SCT to be performed in four patients and allo-SCT in one patient.

Achieving a FDG-PET negative state prior to auto-SCT is desirable to optimise outcomes post transplant.<sup>15</sup> A recent study therefore evaluated the role of BV in achieving FDG-PET-negative status in patients with platinum-refractory HL prior to auto-SCT. Treatment with BV converted 47 % of platinum-refractory patients to FDG-PET negative status. At the time of analysis, 87 % of patients had proceeded to high-dose chemotherapy/auto-SCT.<sup>49</sup> In a phase II study in which BV was incorporated into salvage therapy with the aim of normalising PET, patients (n=40) who achieved normalisation of PET proceeded to SCT while the remainder received two cycles of augmented ICE (ifosfamide, carboplatin, etoposide). The CR rate was 80 % after BV (with or without ICE), almost all (97.5 %) patients were referred for auto-SCT and 30 % of patients were able to avoid ICE salvage therapy.<sup>50</sup> Another recent study has indicated that interim FDG-PET/CT might be a suitable diagnostic approach to predict response to BV in relapsed and refractory HL.<sup>51</sup>

In addition to acting as a bridge to auto-SCT, BV is an attractive option for reducing tumour burden to facilitate consolidative allogeneic SCT (allo-SCT), improving post-transplantation disease-free survival. Fifteen of the patients who participated in the pivotal phase II studies received consolidative allo-SCT following BV treatment.<sup>52</sup> In a recent report, the 2-year PFS of these patients was estimated to be 66 % and the median PFS had not yet been reached. Eleven of the patients were alive and the estimated 2-year survival rate was 80 %.<sup>52</sup>

A retrospective analysis compared 23 HL patients who underwent reduced-intensity conditioning (RIC) allo-HCT with no prior BV exposure with 21 additional HL patients who received BV prior to RIC allo-SCT. The patients who received BV prior to RIC allo-HCT in relapsed HL showed improvements in haematopoietic cell transplantation comorbidity index (HCT-CI), CR status at time of transplant and reduced peri-transplant toxicity.<sup>53</sup> In another study of patients who underwent allo-SCT (n=27), 52 % received BV prior to allo-SCT, and in seven patients, it was the last therapy prior to allo-SCT. In these seven patients the CR rate was 100 %, indicating that a BV-based transplant strategy is useful in this high-risk patient group.<sup>54</sup>

### Brentuximab Vedotin in Relapsed Hodgkin's Lymphoma following Allogeneic Stem Cell Transplantation

There are currently no effective therapeutic options for HL patients who relapse following allo-SCT. BV enhances the graft versus lymphoma response by the induction of immunogenic cell death and may therefore be a promising approach for relapsed HL after allo-SCT.<sup>55</sup> A study (n=25) investigated BV in this setting.<sup>55</sup> An overall ORR of 50 % was reported, with CRR of 38 %. The median progression-free survival (PFS) was 7.8 months. Although most AEs were manageable, nine patients (36 %) discontinued treatment due to AEs. The study concluded that BV was potentially beneficial in selected patients with recurrent HL after allo-SCT.<sup>55</sup> In a report of four cases of patients with HL that relapsed early after allo-SCT, BV in combination with donor lymphocyte infusions induced tumour-specific immunity and sustained clinical remission all patients.<sup>32</sup>

### Brentuximab Vedotin as First-line Treatment

Given the high response rate in the relapsed setting and the manageable toxicity profile, incorporating BV into first-line therapy is an attractive option. In an ongoing phase II study, BV was investigated as front-line therapy in patients aged ≥60 years (n=13). Recently presented results indicated that of the 11 patients with a response assessment, the ORR was 82 % and CR rate was 64 %.<sup>56</sup> This suggests that BV is a promising treatment option in this historically challenging population of patients who either declined or were not eligible for standard chemotherapy.

There is a strong rationale for combining BV with chemotherapy as front-line therapy. A phase I open-label dose-escalation study investigated BV in combination with the standard chemotherapy regimen of ABVD or a modified regimen of doxorubicin, vinblastine and dacarbazine (AVD) treatment in treatment-naïve patients with HL.<sup>57</sup> Serious pulmonary toxicity was reported in 44 % of the ABVD group, leading the FDA to issue a formal warning against the use of BV with bleomycin. However, BV combined with AVD given every 2 weeks was generally well tolerated.<sup>57</sup> In a phase II study of patients with newly diagnosed HL, BV is being investigated as part of targeted BEACOPP. Two modified BEACOPP regimens have been studied: BRECAPP (BV,

etoposide, cyclophosphamide, doxorubicin, procarbazine, prednisone) and BrECADD (BV, etoposide, cyclophosphamide, doxorubicin, dacarbazine, dexamethasone). Preliminary results indicate that these regimens may be well feasible without compromising the efficacy associated with escalated BEACOPP.<sup>58</sup>

An ongoing phase III open-label, study, ECHELON-1, has the primary objective of comparing the modified PFS obtained with BV plus AVD versus that obtained with ABVD for the first-line treatment of advanced HL.<sup>59</sup> The combination of BV and bendamustine is also being investigated in the treatment of relapsed/refractory HL and sALCL in a phase I/II study. Results to date (34 patients evaluable for response) indicate that the combination has a manageable safety profile and has achieved high CRR (82 %), with an ORR 94 %.<sup>60</sup> This regimen therefore represents a promising approach that warrants further investigation.

### Brentuximab Vedotin in Paediatric Patients

The use of BV is also being investigated in younger patient populations. Interim data from a phase I/II open-label, multicentre study with BV in paediatric patients diagnosed with CD30+ relapsed, refractory HL and sALCL yielded encouraging results. The phase I arm of the study established the recommended phase II dose of BV in paediatric patients as 1.8 mg/kg every 3 weeks, and found a CR or PR in 88 % of patients. In the ongoing phase II study, BV was generally well tolerated and showed an ORR to date of 64 %, including 21 % CR.<sup>61,62</sup> Several other clinical studies in paediatric and younger adult patient populations are also underway.<sup>63,64</sup>

### Brentuximab Vedotin in Other CD30-positive Malignancies

In addition to HL and sALCL, CD30 positivity has been reported in other malignancies.<sup>65–67</sup> A phase II investigator-sponsored trial is evaluating the use of BV in patients CD30+ cutaneous T-cell lymphomas, including lymphomatoid papulosis, primary cutaneous anaplastic large cell lymphoma or mycosis fungoides. Among 56 patients enrolled to date, 48 patients have received at least two doses of BV. The ORR was 71 %, with CR in 35 %.<sup>65</sup> An ongoing phase II study is evaluating BV in patients (n=62) with relapsed or refractory CD30+ NHL, including diffuse large cell B-cell lymphomas (DLBCL). To date, in DLBCL, an ORR of 42 % was reported with CR in 16 %; in other B-cell NHL, ORR was 22 % with CR in 11 %.<sup>66</sup>

Sequential treatment regimens with BV and chemotherapy are also being explored. In a phase I study, patients (n=39) with newly diagnosed CD30+ mature T/natural killer (NK)-cell lymphomas (an aggressive subset of NHL) received either sequential treatment with two cycles of BV followed by six cycles of the combination chemotherapy regimen CHOP (cyclophosphamide, doxorubicin, vincristine and prednisone) or the combination regimen of BV plus CHP. BV, administered sequentially with CHOP or in combination with CHP, demonstrated manageable toxicity and substantial antitumour activity: in the sequential regimen, ORR was 85 % with CR in 62 %. In the combined regimen, an ORR of 100 % was reported, with CR in 88 % and a 1-year PFS rate of 71 %.<sup>67</sup> Based on these data, a phase III study, ECHELON-2, is comparing BV and CHP versus CHOP in the treatment of patients with CD30+ mature T-cell lymphomas.<sup>68</sup>

BV is also being tested in other CD30+ nonlymphomatous malignancies,<sup>69,70</sup> relapsed/refractory T/NK lymphomas<sup>71</sup> and in steroid-refractory graft versus host disease.<sup>72</sup>

### Safety and Tolerability of Brentuximab Vedotin

Brentuximab vedotin has a manageable toxicity profile: treatment-related AEs include neutropenia, peripheral neuropathy (PN), nausea, fatigue, thrombocytopenia and diarrhoea.<sup>33,36</sup> In the two pivotal trials, 54 % of patients experienced PN.<sup>73</sup> Of these, grade 3 PN (sensory) was reported by 8 % and 10 % of patients in the HL and sALCL trials, respectively, leading to discontinuation in 8 %. Grade 3 PN (motor) was reported by 4 % and 3 % of patients in the HL and sALCL trials, respectively,<sup>73</sup> leading to discontinuation in 3 %. The BV prescribing information recommended monitoring patients for PN and modifying the dosage accordingly.<sup>73</sup> Most patients showed improvement or resolution of PN symptoms at follow-up: with complete resolution in 49 %, and partial improvement in 31 %. Neutropenia should be managed by dose delay and reduction.<sup>74</sup>

A retrospective analysis of the safety and efficacy of BV compared safety data for older (≥60 years, median age 66) and younger patients (<60 years, median age 32) with relapsed CD30+ lymphomas.<sup>75</sup> Higher rates of anaemia (30 % versus 10 %), peripheral sensory neuropathy (60 % versus 46 %), fatigue (58 % versus 43 %) and AEs more than or equal to grade 3 (70 % versus 56 %) were reported in older patients, but the authors concluded that with appropriate monitoring, BV could be a useful treatment option for older patients with relapsed CD30+ lymphomas. In the study investigating retreatment with BV, the reported AEs were similar in type and frequency to those observed in the BV pivotal trials, with the exception of PN, which was observed in 69 % of patients; however, almost half (48 %) of the patients had pre-existing PN at baseline. Grade 3 or higher events were observed in 48 % of patients; these were generally transient and managed by dose modifications or delays. Deaths due to AEs occurred in three HL patients; none were thought to be related to BV retreatment.<sup>40,76</sup>

Since the approval of BV, several cases of progressive multifocal leukoencephalopathy (PML) have been reported.<sup>77–79</sup> The link to BV is uncertain given that these patients have been exposed to multiple other agents, many of which can cause immunosuppression. This serious AE requires continuing monitoring and a new Boxed Warning highlighting this potential risk has been added to the drug label.<sup>80</sup> BV should be discontinued if PML is suspected.<sup>73</sup> Pancreatitis has recently emerged as a rare but serious toxicity associated with BV.<sup>81,82</sup> Clinicians prescribing BV should evaluate patients who present with prolonged nausea and/or vomiting and abdominal pain for pancreatitis, and should consider pre-treatment biochemical assessments with serum lipase and/or amylase. Moreover, haematologists should be alert to the possibility of such an AE.

The long-term safety of BV is of concern in a patient group that has a high expectation of cure and many years of life ahead. To date, limited data are available on long-term safety, and concerns have been expressed over the depletion of T-cell memory that may result from targeting CD30. In studies to date, however, T-cell depletion has not resulted in clinically significant consequences.

### Summary and Concluding Remarks

Brentuximab vedotin combines several main mechanisms that contribute to its potent antitumour activity. In two pivotal phase II trials, BV demonstrated excellent ORR and CR among patients with relapsed/refractory HL and sALCL. It also has an acceptable toxicity profile, with the most common AEs, PN and neutropenia, being largely reversible. There is a need for more studies with longer follow-up to further

assess the safety and efficacy of BV. Numerous ongoing studies are investigating the use of BV at different stages of disease treatment, both as monotherapy and in combination with chemotherapy.

Brentuximab vedotin has the potential to act as a bridge to SCT, a valuable therapeutic indication. The FDA has changed the indication for duration of drug administration, allowing treatment beyond the

previous 16-cycle limit. Studies are ongoing to examine the role of BV in the pre-auto SCT salvage therapy setting as well as in the post-auto-SCT maintenance setting for relapsed/refractory HL, and in the pre-allo-SCT setting. This success of BV represents a landmark in the development of ADCs and has changed the paradigm of the treatment of HL and sALCL in the relapsed/refractory setting. In the future, it may alter the landscape for earlier settings of treatment as well. ■

- Senter PD, Potent antibody drug conjugates for cancer therapy, *Curr Opin Chem Biol*, 2009;13:235–44.
- Beck A, Reichert JM, Antibody-drug conjugates: Present and future, *MAbs*, 2014;6:15–7.
- Ansell SM, Horwitz SM, Engert A, et al., Phase I/II study of an anti-CD30 monoclonal antibody (MDX-060) in Hodgkin's lymphoma and anaplastic large-cell lymphoma, *J Clin Oncol*, 2007;25:2764–9.
- Forero-Torres A, Leonard JP, Younes A, et al., A phase II study of SGN-30 (anti-CD30 mAb) in Hodgkin lymphoma or systemic anaplastic large cell lymphoma, *Br J Haematol*, 2009;146:171–9.
- Grotmol T, Bray F, Holte H, et al., Frailty modeling of the bimodal age-incidence of Hodgkin lymphoma in the Nordic countries, *Cancer Epidemiol Biomarkers Prev*, 2011;20:1350–7.
- Kelly KM, Hodgson D, Appel B, et al., Children's Oncology Group's 2013 blueprint for research: Hodgkin lymphoma, *Pediatr Blood Cancer*, 2013;60:972–8.
- Connors JM, State-of-the-art therapeutics: Hodgkin's lymphoma, *J Clin Oncol*, 2005;23:6400–8.
- Eichenauer DA, Engert A, Dreyling M, ESMO Guidelines Working Group. Hodgkin's lymphoma: ESMO clinical practice guidelines for diagnosis, treatment and follow-up, *Ann Oncol*, 2011;22(Suppl. 6):vi55–vi58.
- Diehl V, Franklin J, Pfreundschuh M, et al., Standard and increased-dose BEACOPP chemotherapy compared with COPP-ABVD for advanced Hodgkin's disease, *N Engl J Med*, 2003;348:2386–95.
- Diehl V, Fuchs M, Ghos, Will BEACOPP be the standard for high risk Hodgkin lymphoma patients in advanced stages?, *Transfus Apher Sci*, 2007;37:37–41.
- Sureda A, Constans M, Iriando A, et al., Prognostic factors affecting long-term outcome after stem cell transplantation in Hodgkin's lymphoma autografted after a first relapse, *Ann Oncol*, 2005;16:625–33.
- Majhail NS, Weisdorf DJ, Defor TE, et al., Long-term results of autologous stem cell transplantation for primary refractory or relapsed Hodgkin's lymphoma, *Biol Blood Marrow Transplant*, 2006;12:1065–72.
- Schmitz N, Pfistner B, Sextro M, et al., Aggressive conventional chemotherapy compared with high-dose chemotherapy with autologous haemopoietic stem-cell transplantation for relapsed chemosensitive Hodgkin's disease: a randomised trial, *Lancet*, 2002;359:2065–71.
- Colpo A, Hochberg E, Chen YB, Current status of autologous stem cell transplantation in relapsed and refractory Hodgkin's lymphoma, *Oncologist*, 2012;17:80–90.
- Moskowitz AJ, Yahalom J, Kewalramani T, et al., Pretransplantation functional imaging predicts outcome following autologous stem cell transplantation for relapsed and refractory Hodgkin lymphoma, *Blood*, 2010;116:4934–7.
- Burroughs LM, O'Donnell PV, Sandmaier BM, et al., Comparison of outcomes of HLA-matched related, unrelated, or HLA-haploidentical related hematopoietic cell transplantation following nonmyeloablative conditioning for relapsed or refractory Hodgkin lymphoma, *Biol Blood Marrow Transplant*, 2008;14:1279–87.
- Sarina B, Castagna L, Farina L, et al., Allogeneic transplantation improves the overall and progression-free survival of Hodgkin lymphoma patients relapsing after autologous transplantation: a retrospective study based on the time of HLA typing and donor availability, *Blood*, 2010;115:3671–7.
- Ram R, Gooley TA, Maloney DG, et al., Histology and time to progression predict survival for lymphoma recurring after reduced-intensity conditioning and allogeneic hematopoietic cell transplantation, *Biol Blood Marrow Transplant*, 2011;17:1537–45.
- Corradini P, Sarina B, Farina L, Allogeneic transplantation for Hodgkin's lymphoma, *Br J Haematol*, 2011;152:261–72.
- Stein H, Foss HD, Durkop H, et al., CD30(+) anaplastic large cell lymphoma: a review of its histopathologic, genetic, and clinical features, *Blood*, 2000;96:3681–95.
- Lister TA, Armitage JO, Non-Hodgkin's Lymphomas. In: Abeloff MD, Armitage JO, Lichter AS, Niederhuber JE, eds, *Clinical Oncology*, 2nd ed., Philadelphia, PA: Churchill Livingstone, 2000;2658–719.
- Merkel O, Hamacher F, Sift E, et al., Novel therapeutic options in anaplastic large cell lymphoma: molecular targets and immunological tools, *Mol Cancer Ther*, 2011;10:1127–36.
- Sibon D, Fournier M, Briere J, et al., Long-term outcome of adults with systemic anaplastic large-cell lymphoma treated within the Groupe d'Etude des Lymphomes de l'Adulte trials, *J Clin Oncol*, 2012;30:3939–46.
- Le Deley MC, Reiter A, Williams D, et al., Prognostic factors in childhood anaplastic large cell lymphoma: results of a large European intergroup study, *Blood*, 2008;111:1560–6.
- Mosse YP, Balis FM, Lim MS, et al., Efficacy of crizotinib in children with relapsed/refractory ALK-driven tumors including anaplastic large cell lymphoma and neuroblastoma: a Children's Oncology Group phase I consortium study, *J Clin Oncol*, 2012;30(5):950.
- Laimer D, Dolznig H, Kollmann K, et al., PDGFR blockade is a rational and effective therapy for NPM-ALK-driven lymphomas, *Nat Med*, 2012;18:1699–704.
- Sutherland MS, Sanderson RJ, Gordon KA, et al., Lysosomal trafficking and cysteine protease metabolism confer target-specific cytotoxicity by peptide-linked anti-CD30-auristatin conjugates, *J Biol Chem*, 2006;281:10540–7.
- Francisco JA, Cerveny CG, Meyer DL, et al., cAC10-vcMMAE, an anti-CD30-monomethyl auristatin E conjugate with potent and selective antitumor activity, *Blood*, 2003;102:1458–65.
- Okeley NM, Miyamoto JB, Zhang X, et al., Intracellular activation of SGN-35, a potent anti-CD30 antibody-drug conjugate, *Clin Cancer Res*, 2010;16:888–97.
- Younes A, Bartlett NL, Leonard JP, et al., Brentuximab vedotin (SGN-35) for relapsed CD30-positive lymphomas, *N Engl J Med*, 2010;363:1812–21.
- Gruss HJ, Pinto A, Ghoghini A, et al., CD30 ligand expression in nonmalignant and Hodgkin's disease-involved lymphoid tissues, *Am J Pathol*, 1996;149:469–81.
- Theurich S, Malcher J, Wennhold K, et al., Brentuximab vedotin combined with donor lymphocyte infusions for early relapse of Hodgkin lymphoma after allogeneic stem-cell transplantation induces tumor-specific immunity and sustained clinical remission, *J Clin Oncol*, 2013;31:e59–63.
- Younes A, Gopal AK, Smith SE, et al., Results of a pivotal phase II study of brentuximab vedotin for patients with relapsed or refractory Hodgkin's lymphoma, *J Clin Oncol*, 2012;30:2183–9.
- Gopal AK, Chen R, Smith S, et al., The three-year follow-up data and characterization of long-term remissions from an ongoing Phase 2 study of Brentuximab Vedotin in patients with relapsed or refractory Hodgkin Lymphoma. Presented at the American Society of Hematology meeting, New Orleans, 7–10 December 2013; Abstract no 4382, 2013.
- Gopal AK, Chen R, Smith SE, et al., Durable remissions in a pivotal phase 2 study of brentuximab vedotin in relapsed or refractory Hodgkin lymphoma, *Blood*, 2015;125:1236–43.
- Pro B, Advani R, Brice P, et al., Brentuximab vedotin (SGN-35) in patients with relapsed or refractory systemic anaplastic large-cell lymphoma: results of a phase II study, *J Clin Oncol*, 2012;30:2190–6.
- Pro B, Advani R, Brice P, et al., Three year survival results from an ongoing phase 2 study of brentuximab vedotin in patients with relapsed or refractory systemic anaplastic large cell lymphoma, presented at the the American Society of Hematology meeting, New Orleans, 7–10 December 2013; Abstract no 1809, 2013.
- Pro B, Advani R, Brice P, et al., Four-year survival data from an ongoing pivotal phase 2 study of brentuximab vedotin in patients with relapsed or refractory systemic anaplastic large cell lymphoma. Presented at the 56th ASH Annual Meeting and Exposition, 6–9 December 2014, San Francisco, CA; Abstract 3095. Available at: <https://ash.confex.com/ash/2014/webprogram/Paper67039.html> (accessed 26 April 2015), 2014.
- de Claro RA, McGinn K, Kwitkowski V, et al., U.S. Food and Drug Administration approval summary: brentuximab vedotin for the treatment of relapsed Hodgkin lymphoma or relapsed systemic anaplastic large-cell lymphoma, *Clin Cancer Res*, 2012;18:5845–9.
- Bartlett NL, Chen R, Fanale MA, et al., Retreatment with brentuximab vedotin in patients with CD30-positive hematologic malignancies, *J Hematol Oncol*, 2014;7:24.
- Zinzani PL, Viviani S, Anastasia A, et al., Brentuximab vedotin in relapsed/refractory Hodgkin's lymphoma: the Italian experience and results of its use in daily clinical practice outside clinical trials, *Haematologica*, 2013;98:1232–6.
- Sasse S, Rothe A, Goergen H, et al., Brentuximab vedotin (SGN-35) in patients with transplant-naïve relapsed/refractory Hodgkin lymphoma, *Leuk Lymphoma*, 2013;54:2144–8.
- Gibb A, Jones C, Bloor A, et al., Brentuximab vedotin in refractory CD30+ lymphomas: a bridge to allogeneic transplantation in approximately one quarter of patients treated on a Named Patient Programme at a single UK center, *Haematologica*, 2013;98:611–4.
- Garciaz S, Coso D, Peyrade F, et al., Brentuximab vedotin followed by allogeneic transplantation as salvage regimen in patients with relapsed and/or refractory Hodgkin's lymphoma, *Hematol Oncol*, 2014;32:187–91.
- Moskowitz CH, Nademane A, Masszi T, et al., Brentuximab vedotin as consolidation therapy after autologous stem-cell transplantation in patients with Hodgkin's lymphoma at risk of relapse or progression (AETHERA): a randomised, double-blind, placebo-controlled, phase 3 trial, *Lancet*, 2015;385:1853–62.
- Chen R, Wang F, Zhang H, et al., Brentuximab vedotin for treatment of relapsed or refractory malignant lymphoma: results of a systematic review and meta-analysis of prospective studies, *Drug Des Devel Ther*, 2015;9:2277–83.
- Bonthapally V, Wu E, Macalalad A, et al., Brentuximab vedotin in relapsed/refractory Hodgkin lymphoma post-autologous transplant: meta-analysis versus historical data, *Curr Med Res Opin*, 2015;31:993–1001.
- Forero-Torres A, Fanale M, Advani R, et al., Brentuximab vedotin in transplant-naïve patients with relapsed or refractory Hodgkin lymphoma: analysis of two phase I studies, *Oncologist*, 2012;17:1073–80.
- Onishi M, Holmberg L, Shustov AR, et al., Brentuximab vedotin administered to platinum-refractory transplant naïve Hodgkin lymphoma patients can increase the proportion achieving FDG-PET Negative Status, *Blood*, 2013;122:2106.
- Moskowitz AJ, Schoeder H, Yahalom J, et al., PET-adapted sequential salvage therapy with brentuximab vedotin followed by augmented ifosamide, carboplatin, and etoposide for patients with relapsed and refractory Hodgkin's lymphoma: a non-randomised, open-label, single-centre, phase 2 study, *Lancet Oncol*, 2015;16:284–92.
- Kahraman D, Theurich S, Rothe A, et al., 18-Fluorodeoxyglucose positron emission tomography/computed tomography for assessment of response to brentuximab vedotin treatment in relapsed and refractory Hodgkin lymphoma, *Leuk Lymphoma*, 2014;55:811–6.
- Illidge T, Bouabdallah R, Chen R, et al., Allogeneic transplant following brentuximab vedotin in patients with relapsed or refractory Hodgkin lymphoma and systemic anaplastic large cell lymphoma, *Leuk Lymphoma*, 2014;1–34.
- Chen R, Palmer J, Tsai N-C, et al., Brentuximab vedotin improves HCT-CI, CR status, and peri-transplant toxicity in patients with relapsed/refractory Hodgkin lymphoma heading to RIC allo-HCT. Presented at the American Society of Hematology meeting, New Orleans, 7–10 December 2013; Abstract no 3374, 2013.
- Anderlini P, Saliba RM, Ledesma BS, et al., Reduced-intensity conditioning (RIC) and allogeneic stem cell transplantation (allo-SCT) for relapsed/refractory Hodgkin Lymphoma (HL) in the brentuximab vedotin era: Favorable overall and progression-free survival (OS/PFS) with low transplant-related mortality (TRM), *Clin Adv Hematol Oncol*, 2014;12(Suppl. 6):15–7.
- Gopal AK, Ramchandren R, O'Connor OA, et al., Safety and efficacy of brentuximab vedotin for Hodgkin lymphoma recurring after allogeneic stem cell transplantation, *Blood*, 2012;120:560–8.
- Yasenchak CA, Chen R, Sharmar JP, et al., A phase 2 study of single-agent brentuximab vedotin for front-line therapy of Hodgkin lymphoma in patients age 60 years and above: Interim Results. Presented at the the American Society of Hematology meeting, New Orleans, 7–10 December 2013; Abstract no 4389, 2013.
- Younes A, Connors JM, Park SI, et al., Brentuximab vedotin combined with ABVD or AVD for patients with newly diagnosed Hodgkin's lymphoma: a phase 1, open-label, dose-escalation study, *Lancet Oncol*, 2013;14:1348–56.
- Borchmann P, Eichenauer DA, Plütschow A, et al., Targeted Beacop variants in patients with newly diagnosed advanced stage classical Hodgkin Lymphoma: Interim results of a randomized phase II study. Presented at the the American Society of Hematology meeting, New Orleans, 7–10 December 2013; Abstract no 4344, 2013.
- Ansell SM, Connors JM, Park SI, et al., Front-line therapy with brentuximab vedotin combined with ABVD or AVD in patients with newly diagnosed advanced stage Hodgkin lymphoma; presented at the 9th International Symposium on Hodgkin lymphoma; 12–15 October 2013, Cologne, Germany; Abstract P005, 2013.
- LaCasce A, Bociek RG, Matous J, et al., Brentuximab vedotin in combination with bendamustine for patients with Hodgkin lymphoma who are relapsed or refractory after frontline therapy presented at the 56th ASH Annual Meeting and Exposition, 6–9 December, 2014, San Francisco, CA. Abstract 293.
- Neville KF, Phase I/II study of brentuximab vedotin in pediatric patients with relapsed or refractory Hodgkin lymphoma or systemic anaplastic large cell lymphoma: Interim Phase I safety data. Poster presentation at the American Society of Clinical Oncology (ASCO) Annual Meeting held 31 May–4 June 2013, Chicago, IL. Abstract no 36C, 2013.
- Locatelli F, Neville KA, Rosolen A, et al., Phase 1/2 study of brentuximab vedotin in pediatric patients with relapsed or refractory (R/R) Hodgkin lymphoma (HL) or systemic anaplastic large-cell lymphoma (sALCL): Preliminary phase 2 data for brentuximab vedotin 1.8 Mg/Kg in the HL study arm, *Blood*, 2013;122:4378.

63. National Cancer Institute (NCI) brentuximab vedotin and gemcitabine hydrochloride in treating younger patients with relapsed or refractory Hodgkin lymphoma. Available at: <http://clinicaltrials.gov/show/NCT01780662> (accessed 16 January 2014).
64. St. Jude Children's Research Hospital Adcetris (brentuximab vedotin), combination chemotherapy, and radiation therapy in treating younger patients with stage IIB, IIIB and IV Hodgkin lymphoma. Available at: <http://clinicaltrials.gov/show/NCT01920932> (accessed 16 January 2014).
65. Duvic M, Tetzlaff M, Clos AL, et al., Phase II trial of brentuximab vedotin for CD30+ cutaneous T-Cell lymphomas and lymphoproliferative disorders. Presented at the the American Society of Hematology meeting, New Orleans, 7–10 December 2013; Abstract no 4367, 2013.
66. A phase 2 study of brentuximab vedotin in patients with relapsed or refractory CD30-positive non-Hodgkin lymphomas: interim results in patients with DLBCL and other B-cell lymphomas, *Clin Adv Hematol Oncol*, 2014;12:3–4.
67. Fanale MA, Horwitz SM, Forero-Torres A, et al., Brentuximab vedotin administered before, during, and after multi-agent chemotherapy in patients (pts) with newly-diagnosed CD30+ mature T- and NK-cell lymphomas. Presented at the American Society of Hematology meeting, New Orleans, 7–10 December 2013; Abstract no 4386, 2013.
68. O'Connor OA, Pro B, Illidge T, et al., Phase III trial of brentuximab vedotin and CHP versus CHOP in the frontline treatment of patients (pts) with CD30+ mature T-cell lymphomas (MTCL), *J Clin Oncol*, 2013;31(suppl); abstract TPS8611).
69. Seattle Genetics, Inc. Brentuximab vedotin in patients with CD30-positive nonlymphomatous malignancies. NCT01461538. ClinicalTrials.gov website. Available at: <http://www.clinicaltrials.gov/ct2/show/NCT01461538> (accessed 20 January 2014).
70. Albany C, Feldman DR, Garbo LE, et al., Antitumor activity of brentuximab vedotin in CD30 positive refractory germ cell tumors, *J Clin Oncol*, 2013;31(Suppl. 6):abstr 327).
71. Horwitz SM, Advani RH, Bartlett NL, et al., Objective responses in relapsed T-cell lymphomas with single-agent brentuximab vedotin, *Blood*, 2014;123:3095–100.
72. Fred Hutchinson Cancer Research Center/University of Washington Cancer Consortium, brentuximab vedotin in treating patients with steroid-resistant acute graft-versus-host disease. Available at: <http://www.clinicaltrials.gov/ct2/show/NCT01616680> (accessed 17 October 2015).
73. ADCETRIS [Prescribing Information]: Seattle Genetics Inc; 2012. Available at: [http://www.seattlegenetics.com/pdf/adcetris\\_USPI.pdf](http://www.seattlegenetics.com/pdf/adcetris_USPI.pdf) (accessed 17 October 2015).
74. SmPC, Acetris; summary of product characteristics. 20140320-II/0010-Version 8, 2014.
75. Gopal AK, Bartlett NL, Forero-Torres A, et al., Brentuximab vedotin in patients aged 60 years or older with relapsed or refractory CD30-positive lymphomas: a retrospective evaluation of safety and efficacy, *Leuk Lymphoma*, 2014;55:2328–34.
76. Fanale MM, Whiting NC, Neylon E, et al., Treatment strategies to optimize outcomes with brentuximab vedotin: Management of common and rare toxicities, *Int J Target Ther Cancer*, 2015;April:36–45.
77. Wagner-Johnston ND, Bartlett NL, Cashen A, et al., Progressive multifocal leukoencephalopathy in a patient with Hodgkin lymphoma treated with brentuximab vedotin, *Leuk Lymphoma*, 2012;53:2283–6.
78. Jalan P, Mahajan A, Pandav V, et al., Brentuximab associated progressive multifocal leukoencephalopathy, *Clin Neurol Neurosurg*, 2012;114:1335–7.
79. Carson KR, Newsome SD, Kim EJ, et al., Progressive multifocal leukoencephalopathy associated with brentuximab vedotin therapy: A report of 5 cases from the Southern Network on Adverse Reactions (SONAR) project, *Cancer*, 2014;120:2464–71.
80. FDA, FDA drug safety communication: New boxed warning and contraindication for Adcetris (brentuximab vedotin). Food and Drug Administration website. Available at: <http://www.fda.gov/drugs/drugsafety/ucm287668.htm> (accessed 17 October 2015).
81. Gandhi MD, Evens AM, Fenske TS, et al., Pancreatitis in patients treated with brentuximab vedotin: a previously unrecognized serious adverse event, *Blood*, 2014;123:2895–7.
82. Urru SA, Mariotti E, Carta P, et al., Acute pancreatitis following brentuximab vedotin therapy for refractory hodgkin lymphoma: a case report, *Drugs R D*, 2014;14:9–11.
83. Moskowitz A, Schoder H., Gerecitano, J.F. et al., FDG-PET Adapted Sequential Therapy With Brentuximab Vedotin and Augmented ICE Followed By Autologous Stem Cell Transplant For Relapsed and Refractory Hodgkin Lymphoma. Presented at the the American Society of Hematology meeting, New Orleans, 7-10 December 2013; Abstract no 2099, 2013;
84. Chen X, Soma LA, Fromm JR, Targeted therapy for Hodgkin lymphoma and systemic anaplastic large cell lymphoma: focus on brentuximab vedotin, *Onco Targets Ther*, 2013;7:45-56.
85. Katz J, Janik JE, Younes A, Brentuximab Vedotin (SGN-35), *Clin Cancer Res*, 2011;17:6428-36.