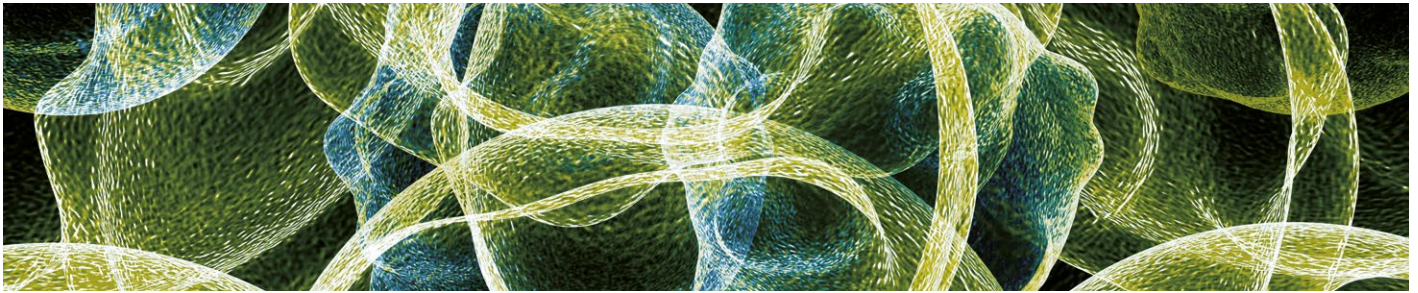


Erratum to: Cytogenetic, Inflammatory, Immunologic, and Infectious Basis for Dysplastic Hematopoiesis

Pedro Alcedo,¹ Enrique Andrade,¹ Hussein Hamad,^{1,2} and Gustavo Rivero^{1,2,3}

1. Section of Hematology/Oncology, Baylor St Luke's Medical Center, Houston, Texas, US; 2. Department of Internal Medicine, Section of Hematology and Oncology, Baylor College of Medicine, Houston, Texas, US; 3. The Dan L Duncan Comprehensive Cancer Center at Baylor College of Medicine, Houston, Texas, US



Citation: *Oncology & Hematology Review*, 2017;14(1):[online only]

Erratum to: *Oncology & Hematology Review*, 2017;13(2):81–91 DOI: <https://doi.org/10.17925/OHR.2017.13.02.81>

In the originally published article there was an error in the abbreviations for *Figure 1*. The abbreviation “MEP” was incorrectly defined as “monoethyl phosphatate”; this should read “megakaryocytic erythroid progenitor”. □